



NEUROSURGERY TODAY

CHANGING TRENDS IN OUTCOME

Partha P. Bishnu

MS; MCh

NEUROSURGEON

Institute of Neurosciences

Narayana Health, R N Tagore Hospital, Kolkata

Rabindranath Tagore International Institute of Cardiac Sciences(RTIICS).

&

Narayana Superspecialty Hospital,(West Bank -2) Howrah,

KOLKATA

+91 9830834566 (Wats app number)



 **NH Rabindranath Tagore™**
International Institute of Cardiac Sciences
Unit of Narayana Health



NEUROSCIENCES—BRAIN AND SPINE CARE

NEUROSCIENCES PROGRAM

NEUROEMERGENCY 24X7 FOR STROKE & TRAUMA

COMPLEX BRAIN AND SPINAL CORD TUMOURS

PEDIATRIC BRAIN AND SPINE SURGERY

MINIMAL ACCESS SPINE SURGERY

COMPREHENSIVE STROKE CARE- STROKE UNIT

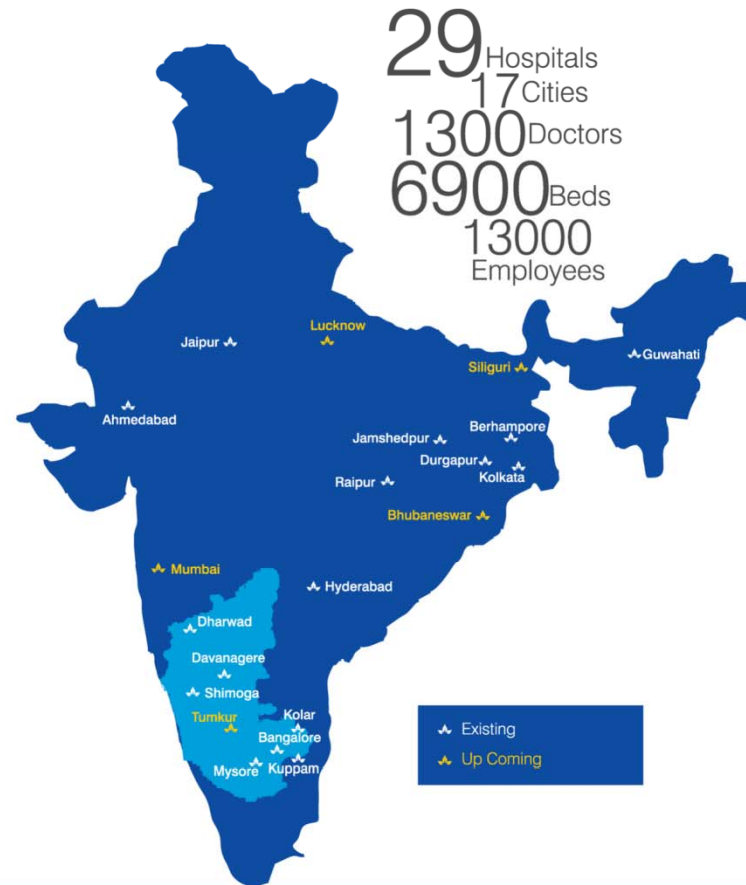
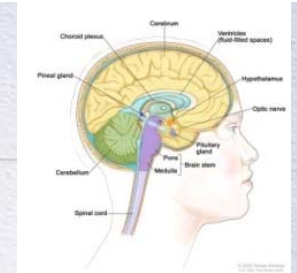
COMPREHENSIVE EPILEPSY CARE- VIDEO EEG LAB

STEREOTACTIC & FUNCTIONAL NEUROSURGERY



NH Rabindranath Tagore
International Institute of Cardiac Sciences

Unit of Narayana Health



Narayana Hrudayalaya Hospitals is now Narayana Health

NEUROSCIENCES—BRAIN AND SPINE CARE

NEUROSURGERY

- fear of paralysis following brain / spinal surgery
- fear of survival following brain surgery
- doubts about usefulness of surgery in brain /spine
- not sure of good / improved outcome

- অসুত্রোপচার প্রয়োজন ?
- মস্তষ্কিক অসুত্রোপচার নিরিপদ ?
- মরুদগুড সার্জারি নিরিপদ ?
- অপারেশেন পর ঠকি হয়ে যাবে ?

- প্রযুক্তি নিরাপদ পরিবেশ সৃষ্টি
- দক্ষতা – সার্জারি নিরাপদ
- কম হাসপাতালে থাকার
প্রয়োজনীয়
- চিকিৎসার খরচ ন্যায্য
-

Evolving Trends Brain & Spine Surgery

BASIC & CLINICAL RESEARCH

TECHNOLOGY- INNOVATIONS

EVIDENCE BASED PRACTICE



বর্ধতি নরিাপত্ৰা

PATIENT SAFETY

IMPROVED OUTCOME



Reducing Morbidity & Mortality

BRAIN TUMOURS

SPINAL SURGERY

STROKE & CEREBROVASCULAR SURGERY

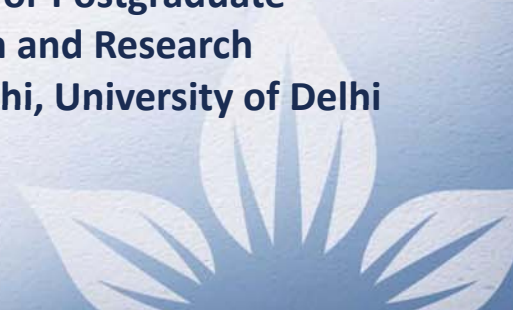ANEURYSMS AND AVMs

EPILEPSY

TRAUMATIC BRAIN INJURY



**GB Pant Institute for Postgraduate
Medical Education and Research
Institute, New Delhi, University of Delhi**





EARLY DETECTION & ACCURATE LOCALISATION

প্রাথমিক ডায়াগনসিস

† HEADACHE- মাথা ব্যাথা

† EPILEPSY- মৃগীরোগ



EARLY DETECTION

SEVERE HEADACHE

YOUNG AND MIDDLE- AGED

MIGRAINE, CLUSTER HEADACHES

SUBARACHNOID HEMORRHAGE

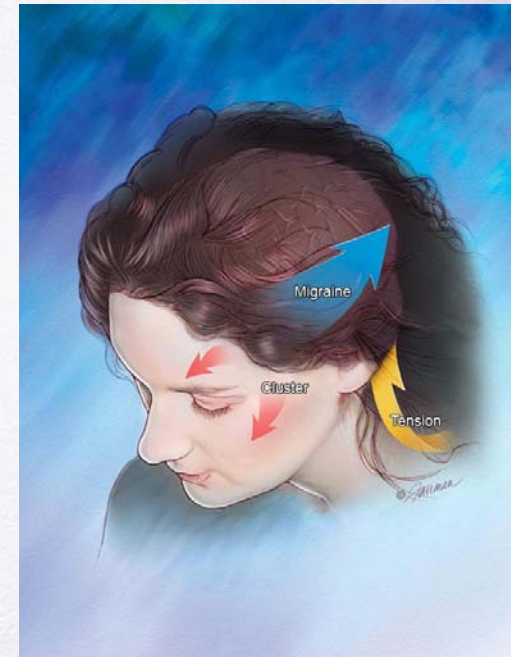
INTRACRANIAL HEMORRHAGE

RAISED INTRACRANIAL PRESSURE

(Brain Tumour)

PITUITARY APOPLEXY

INTRACRANIAL VENOUS THROMBOSIS



EARLY DETECTION

SEVERE HEADACHE

ELDERLY

CHRONIC SUBDURAL HEMATOMA

STROKE

BRAIN TUMOUR



SEVERE HEADACHE

CHILDREN

MIGRAINE

BRAIN TUMOUR

MENINGITIS


HYDROCEPHALUS



HEADACHE EPILEPSY

প্রাথমিক ডায়াগনসিস

**ALWAYS HAVE A HIGH SUSPICION
ALWAYS INVESTIGATE WITH MRI**



CANCER BURDEN: BRAIN TUMOURS

- Brain tumours are second only to stroke as the leading cause of disability in neurological diseases.
- Second common cause of death due to cancer
- Brain tumors in children are the most common solid tumor and, after leukemia, the most common cause of pediatric cancer

Adult & Paediatric

BRAIN TUMORS - EARLY DIAGNOSIS



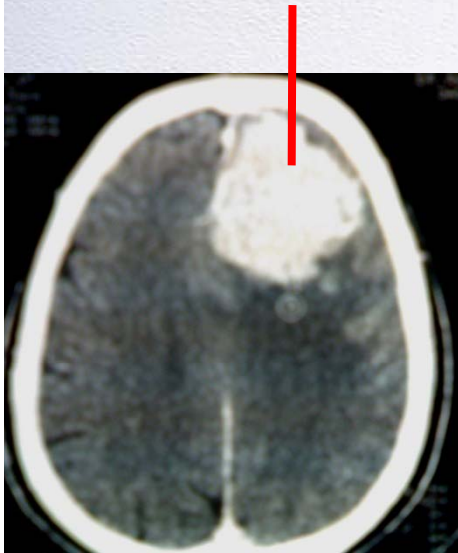55 Y Male, HEADACHE AND HEMIPARESIS

Pre op Tumor Embolisation done to minimise
blood loss during surgery

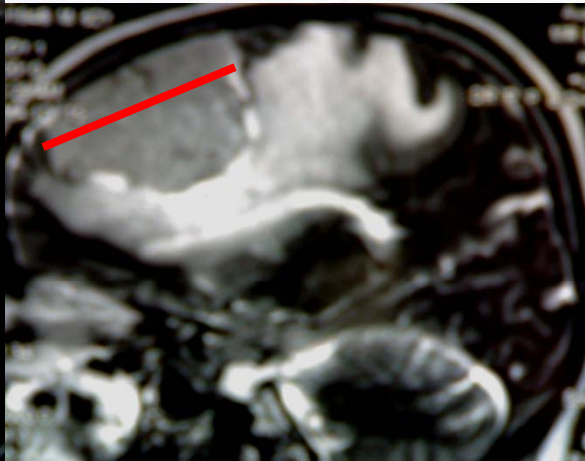COMPLETE RESECTION

NO NEW NEUROLOGICAL DEFICIT

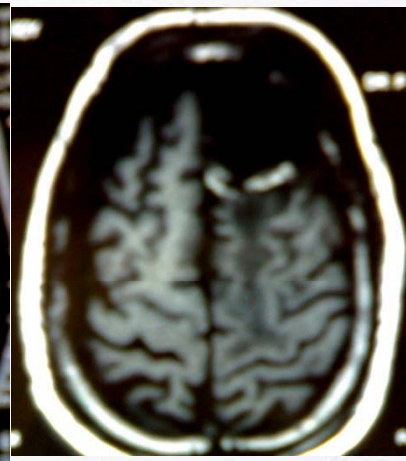
COMPLETE RECOVERY



CT SCAN



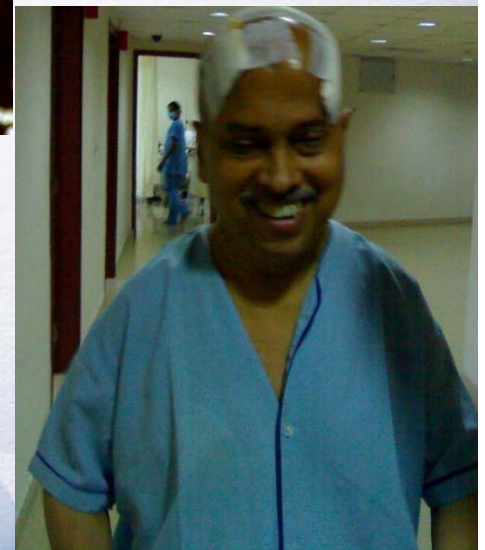MRI SCAN



POST OP MRI

Diagnosis- MENINGIOMA

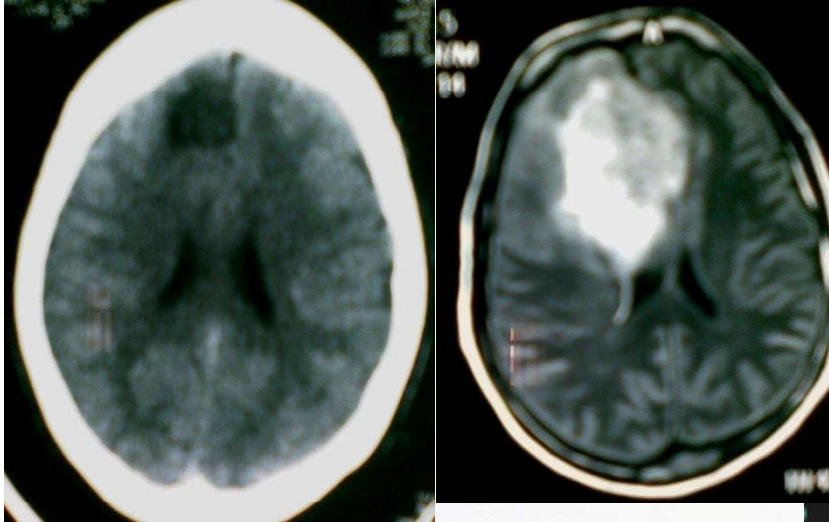
INS. NEUROSCIENCES KOLKATA(IN-K)



BRAIN TUMORS

HEADACHE & SEIZURES

MRI SCAN



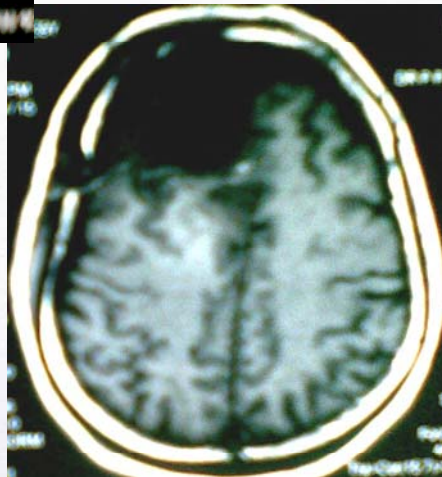
PREOPERATIVE CT & MRI SCANS

35 Yrs , lady from Tripura

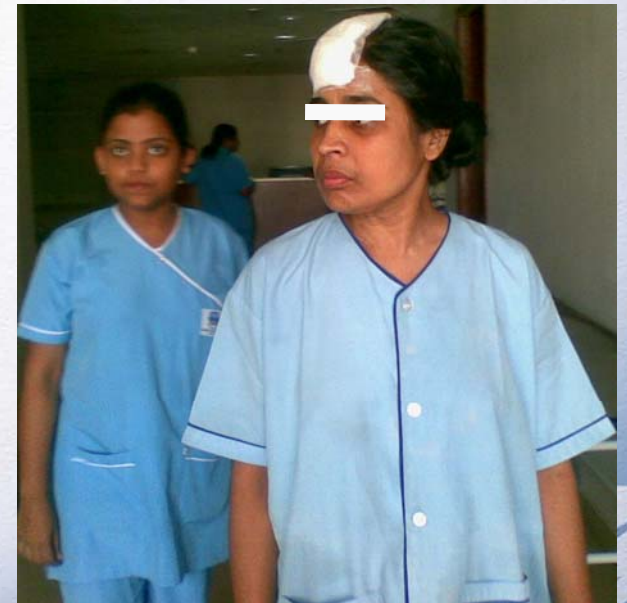LOW GRADE ASTROCYTOMA

COMPLETE RECOVERY

NO NEUROLOGICAL DEFICIT



POST OPERATIVE MRI

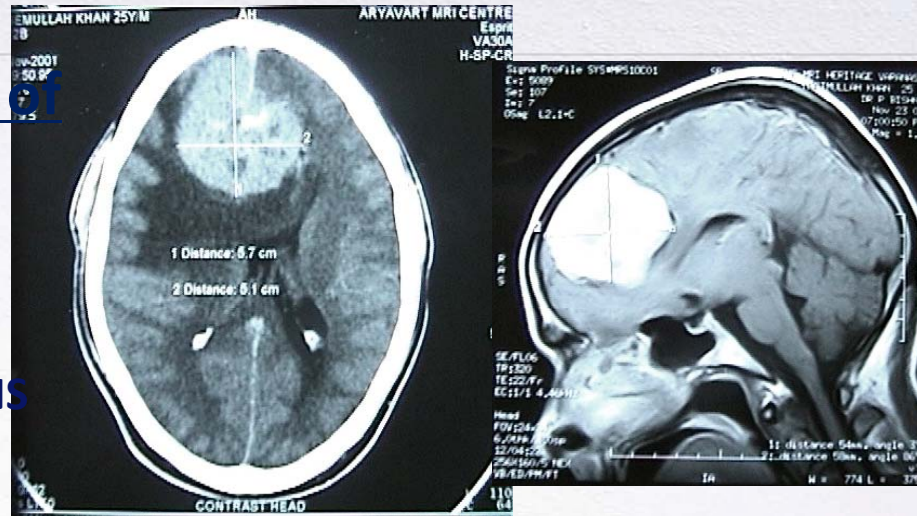


BRAIN TUMOURS DELAY IN DIAGNOSIS

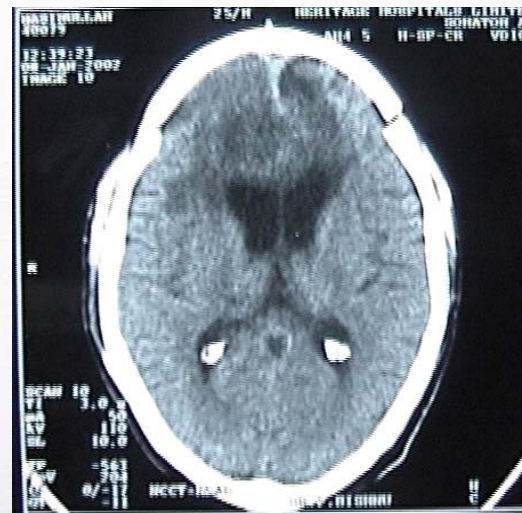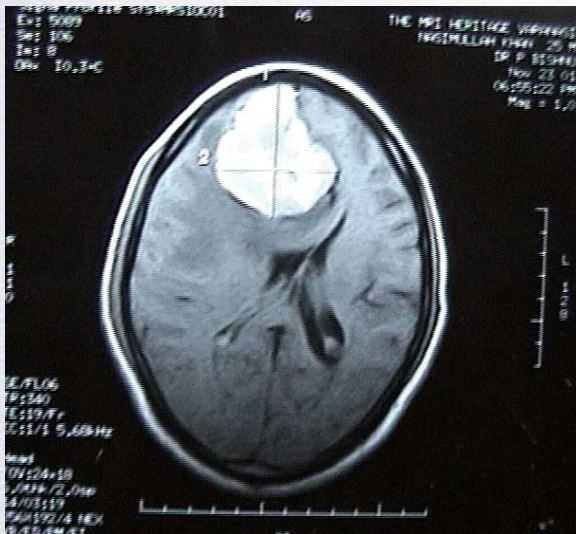


Headache, Seizures, Dimness of Vision- 6months, Bed-ridden for 4 weeks


PREOPERATIVE CT & MRI SCANS



Diagnosis—Bifrontal Meningioma



Post-Op CT Scan



Post-Op Clinical Status

Raised Pressure Headache



Non-specific- earliest feature



Bursting



Morning headache- 50%



Waking up at night due to pain



**Aggravated by bending, coughing,
sneezing**



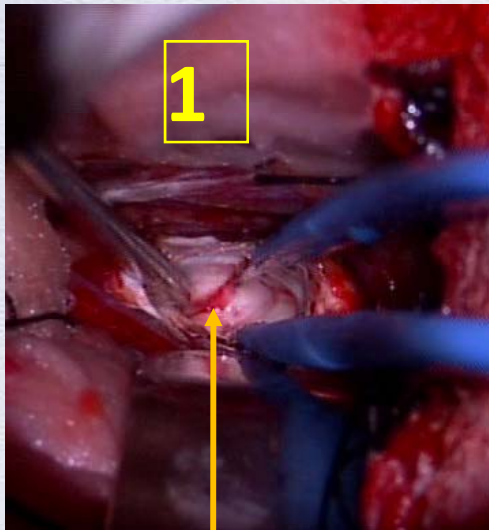
**Associated with vomiting, visual blurring,
features due to underlying lesion**



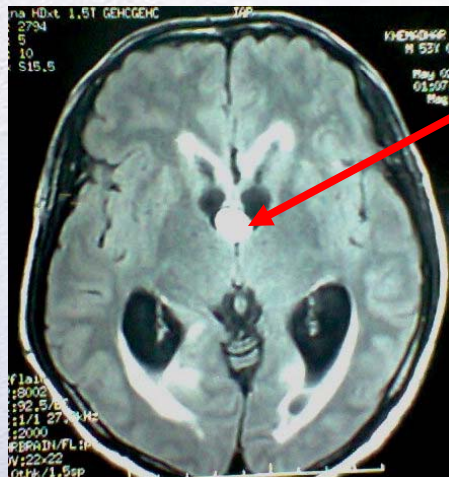
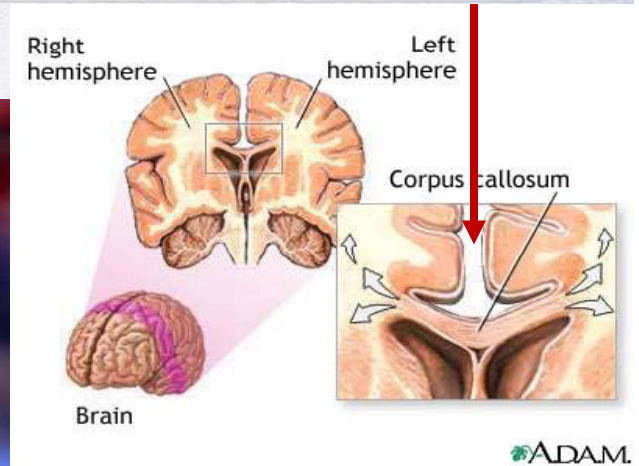
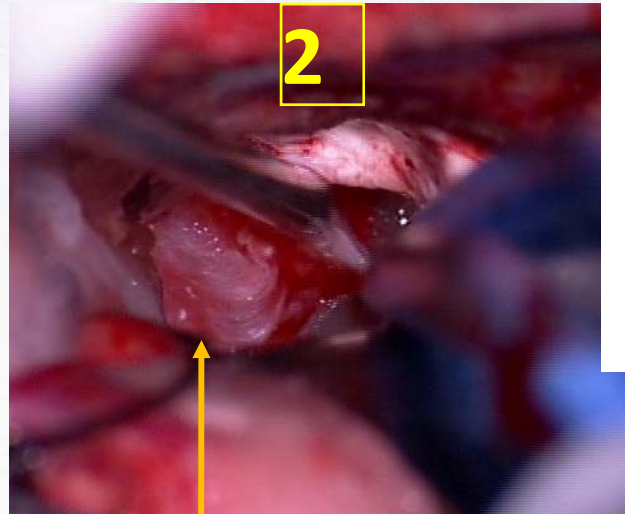
Papilloedema- 50%



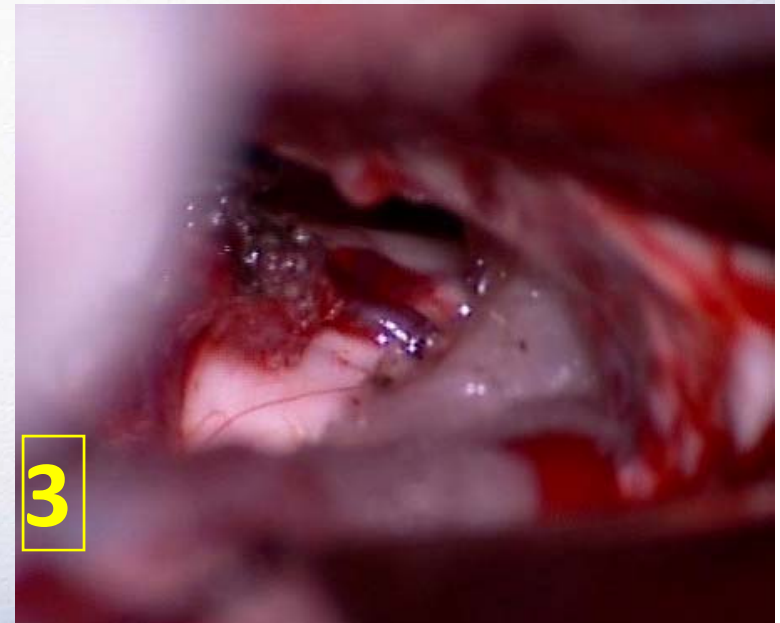
INTRAOPERATIVE MICROPHOTOGRAPH - THIRD VENTRICLE SURGERY HIGH MAGNIFICATION



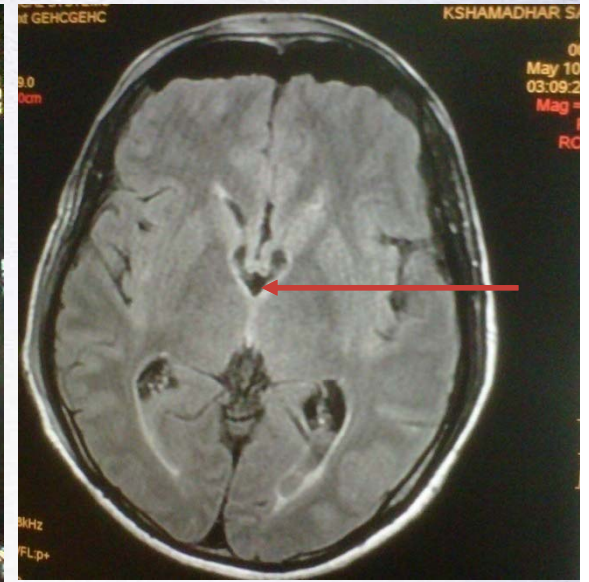
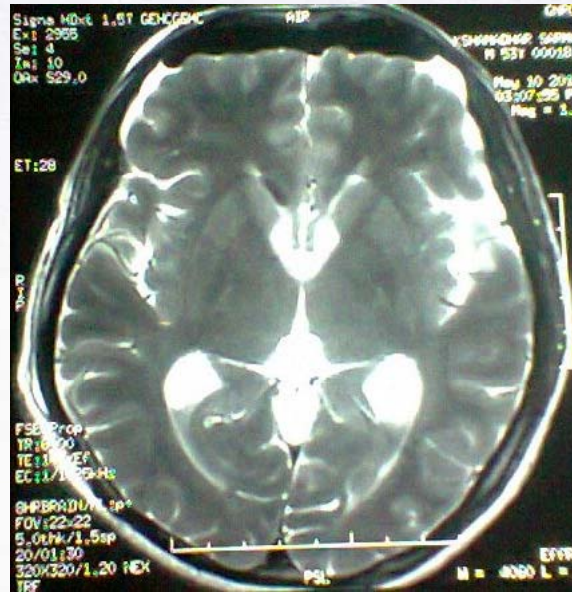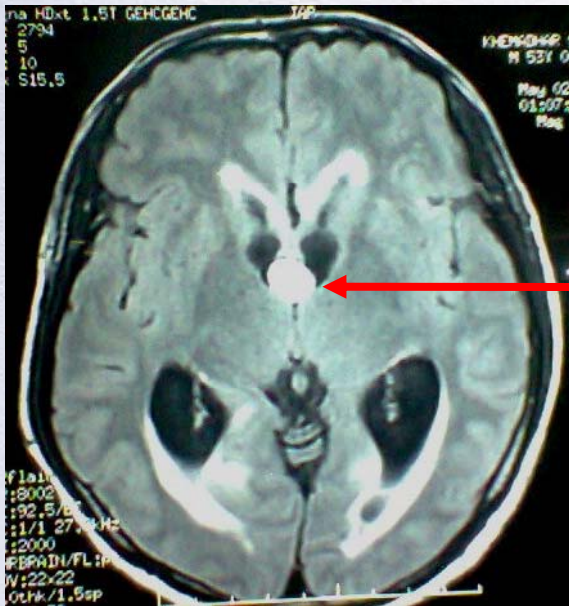
SPLITTING OF CORPUS CALLOSUM



**COLLOID CYST
AD, 45Y M,
OCCASIONAL
HEADACHE**

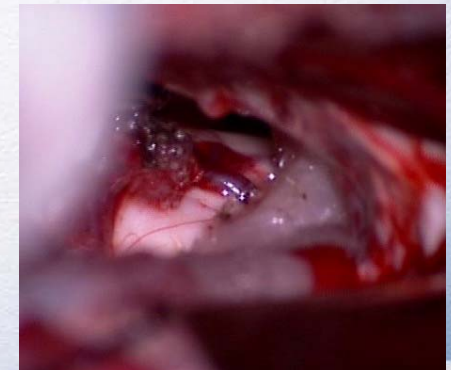
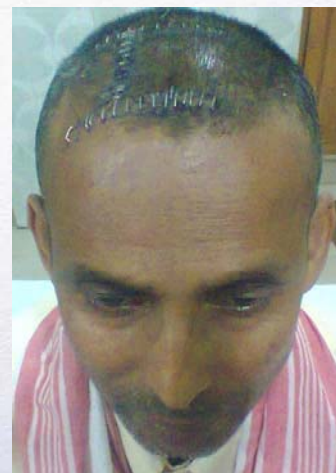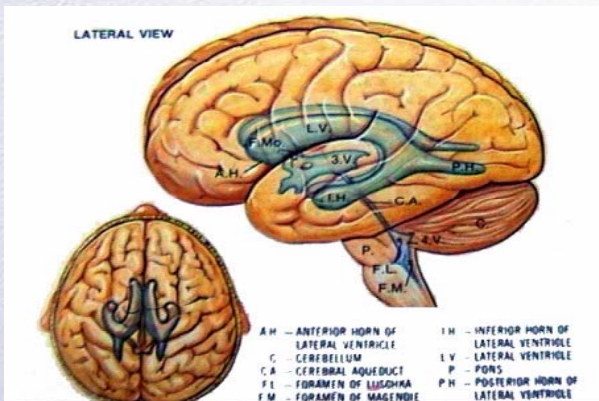


TRANSCALLOSAL TRANSVENTRICULAR MICROSURGICAL EXCISION



POST OP MRI SCAN

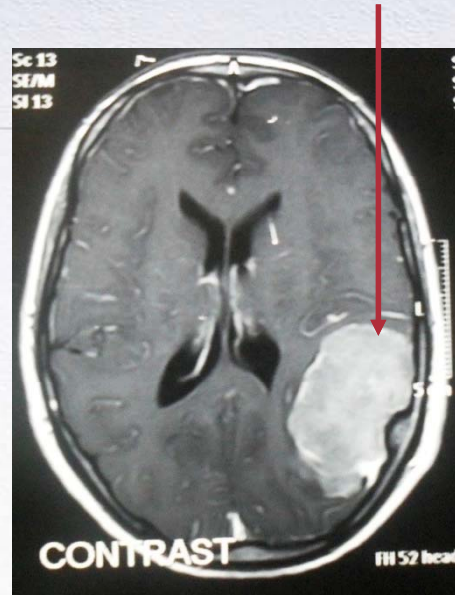PREOPERATIVE MRI SCAN



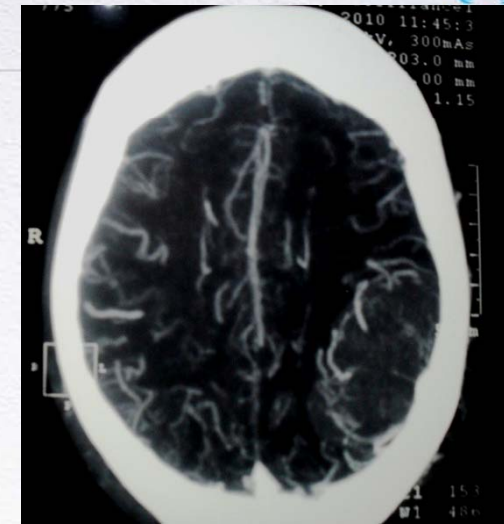
22Y,F
Headache off and on
One episode of Seizure



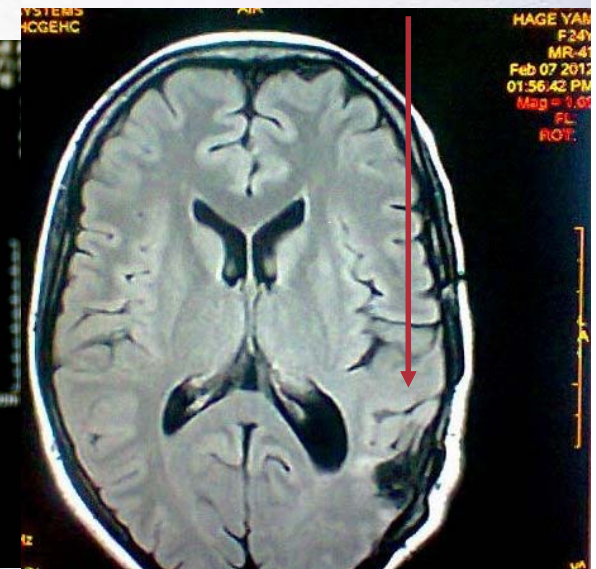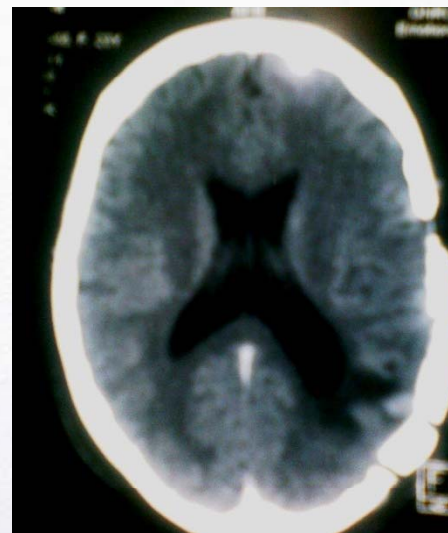
**TOTAL
MICROSURGICAL
EXCISION
DX : MENINGIOMA**



PREOP MRI



MR ANGIO SCAN



POST OPERATIVE CT & FOLLOW UP MR SCAN

HEADACHE WITH NEUROLOGICAL SYMPTOMS



HEADACHE ONLY 0.6-1.4%

PREVALENCE OF HEADACHE 72%

BRAIN TUMORS

HEADACHE + ASSOCIATED SYMPTOMS 14%

EPILEPSY 30%

NEURO IMAGING

MRI SCAN



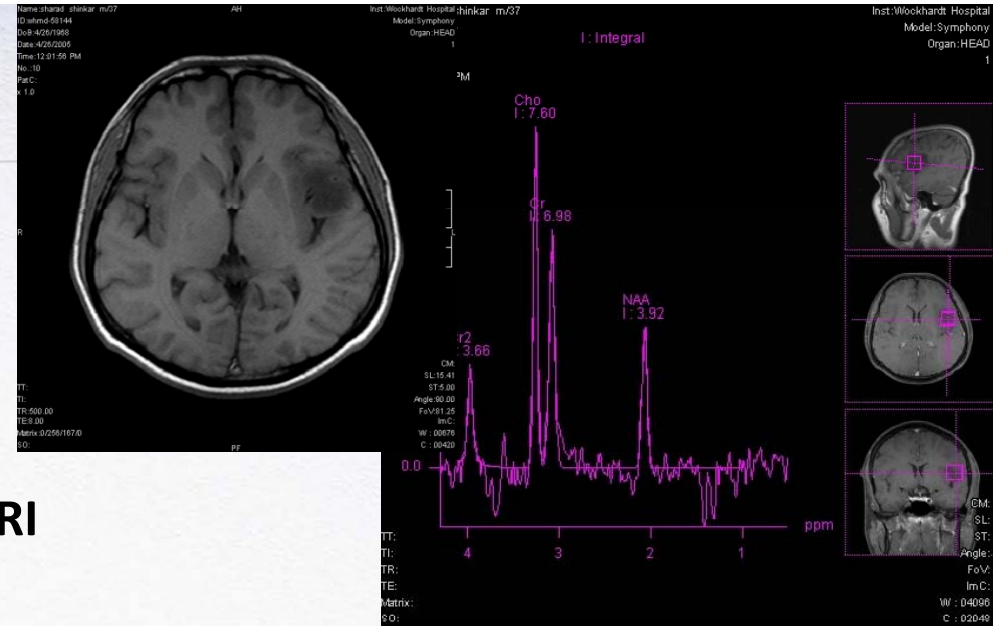
STRUCTURE OF THE BRAIN & SPINAL CORD



PHYSIOLOGY OF THE BRAIN- fMRI



BIOCHEMICAL FEATURES OF LESIONS



CT ANGIOGRAPHY

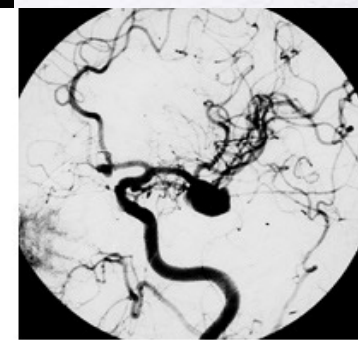
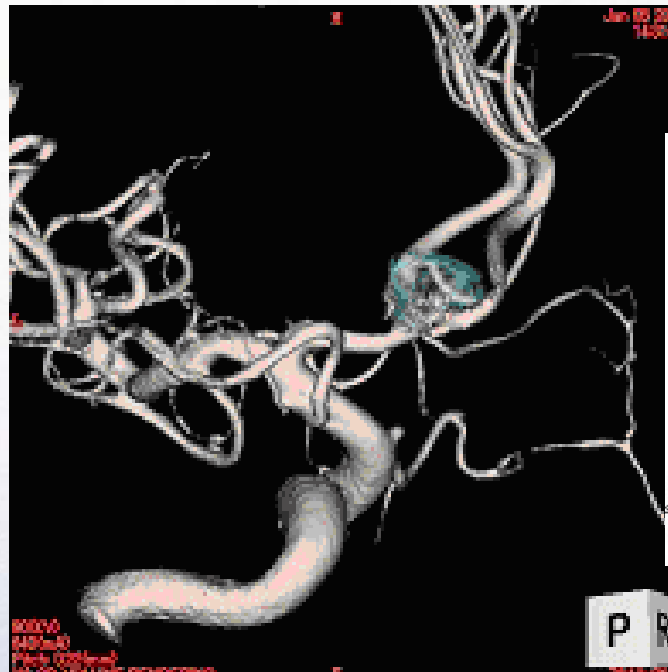
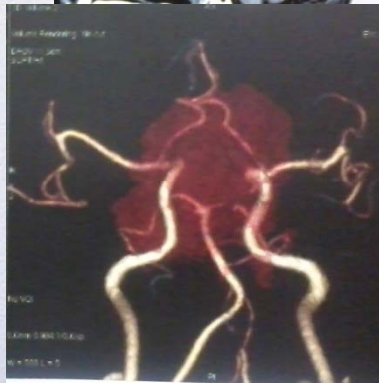
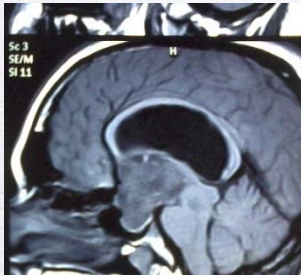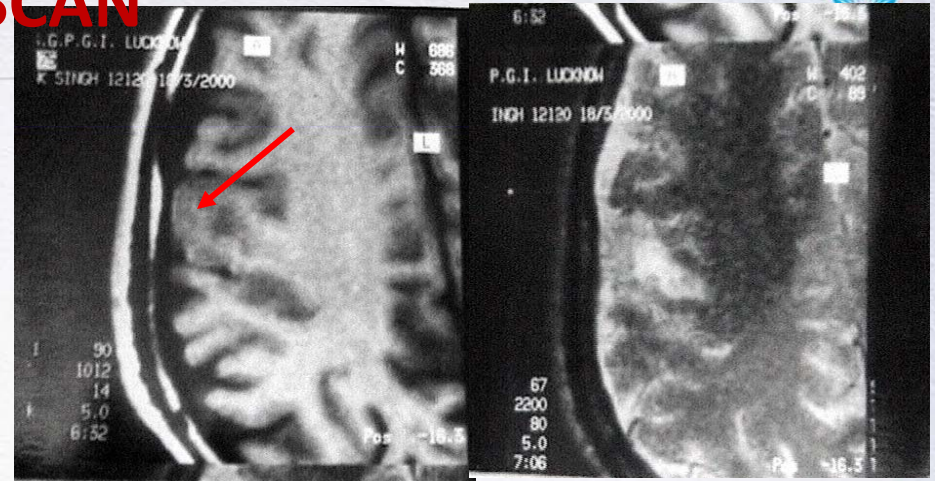


FIGURE 1. Lateral view of cerebral angiogram showing saccular aneurysms of the middle cerebral and anterior communicating arteries. See text for further details

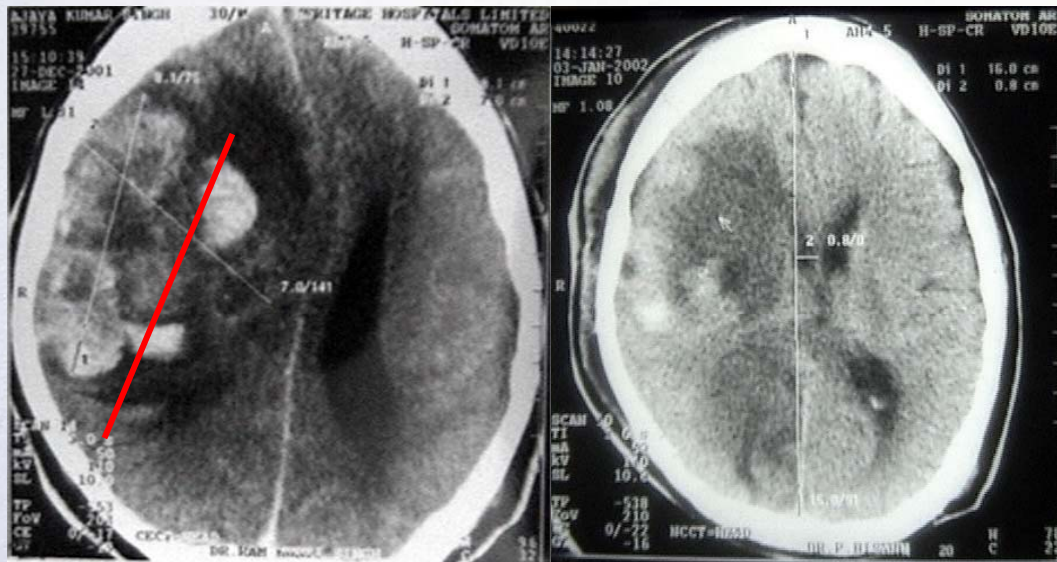BRAIN TUMOUR

MRI SCAN

28Y M, Seizures and Headache: 2Yrs;
Loss of Consciousness: 5 Days Deep
Coma with Non Reacting Pupils
Poor Outcome



MRI Scan : 2 yrs before Admission



CT Scan on Admission

Post-Op CT Scan

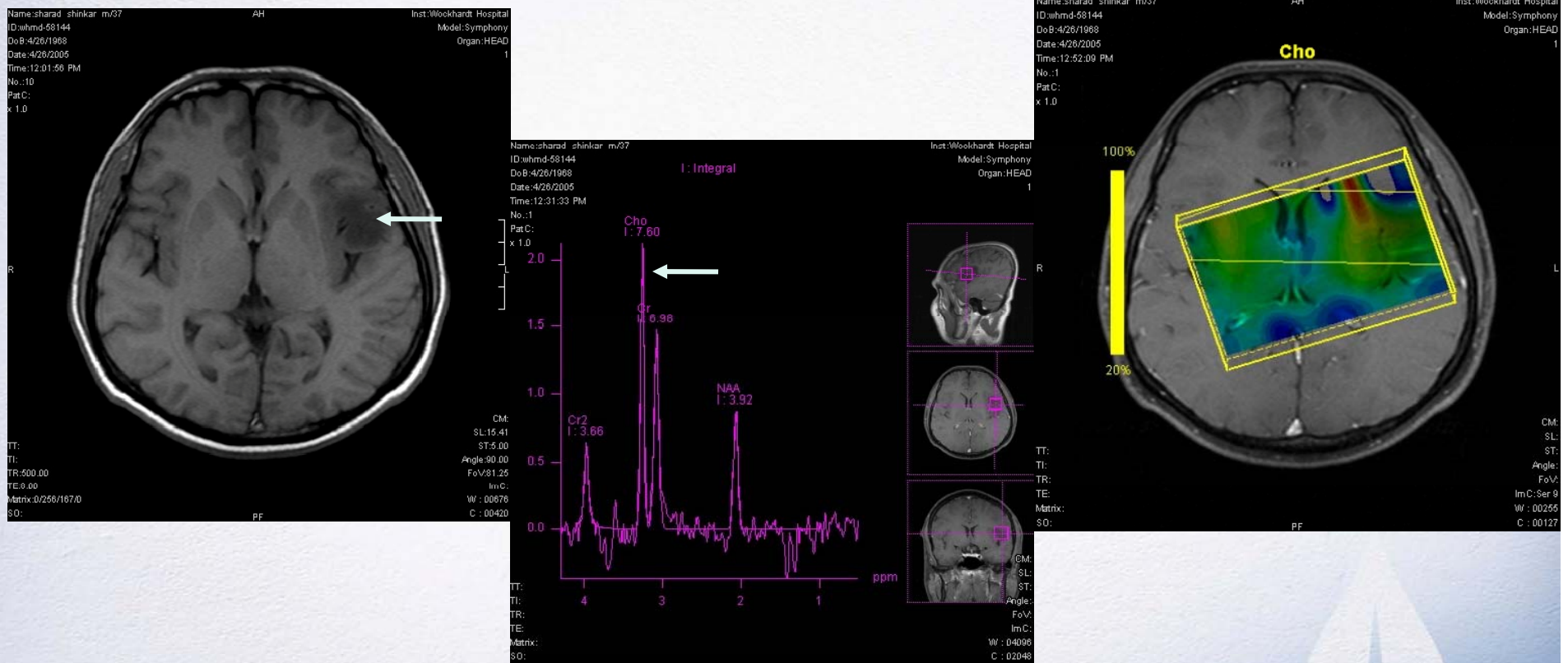
EARLY DIAGNOSIS
NEOPLASTIC LESIONS
MRS SCAN

Diagnosis: High grade Glioma
Malignant Astrocytoma

BRAIN TUMOR SURGERY & MRI



3 TESLA MRI & MR Spectroscopy



Tumors, Recurrence, Metastases



Pharmacotherapy

“ Steroids & Frusemide Edema & ↑ ICP

(Dexamethasone, lasix)

“ Anti Epileptics (Leveterecetam) Seizures

“ Dopa Agonists- Pituitary Adenomas

“ Hormone Replacement Pituitary Surgery

“ Adjuvant Chemotherapy-

Temozolamide

-Malignant Gliomas

**Vincristine, CCNU,
 CisPlatin**

-Medulloblastomas

HEADACHE WITH NEUROLOGICAL SYMPTOMS



HEADACHE ONLY

0.6-14%

BRAIN TUMORS


**HEADACHE WITH
ASSOCIATED SYMPTOMS**



HEADACHE EPILEPSY

প্রাথমিক ডায়াগনসিস

**ALWAYS HAVE A HIGH SUSPICION
ALWAYS INVESTIGATE WITH MRI**



CHALLENGES IN NEUROSURGERY



PRESERVE NEUROLOGICAL FUNCTION

REVERSE THE NEUROLOGICAL DEFICIT

Brain Tumors:

- **Early Diagnosis**
- **Minimally Invasive Brain & Spine Surgery**
- **Multi disciplinary/modality therapy**



MICROSURGERY

- প্রযুক্তি নিরাপদ পরিবেশ সৃষ্টি
- দক্ষতা – সার্জারি নিরাপদ
- কম হাসপাতালে থাকার
প্রয়োজনীয়
- চিকিৎসার খরচ ন্যায্য
-

স্নায়ুবিজ্ঞান ইনস্টিটিউট নিউরোসার্জারি

- প্রযুক্তি নিরাপদ পরিবেশ সৃষ্টি
- দক্ষতা – সার্জারি নিরাপদ
- কম হাসপাতালে থাকার
প্রয়োজনীয়
- চিকিৎসার খরচ ন্যায্য
-

নিউরোসার্জারি

আধুনিক যন্ত্রপাতি

MICROSURGERY

STRATEGIES: BRAIN TUMOUR SURGERY

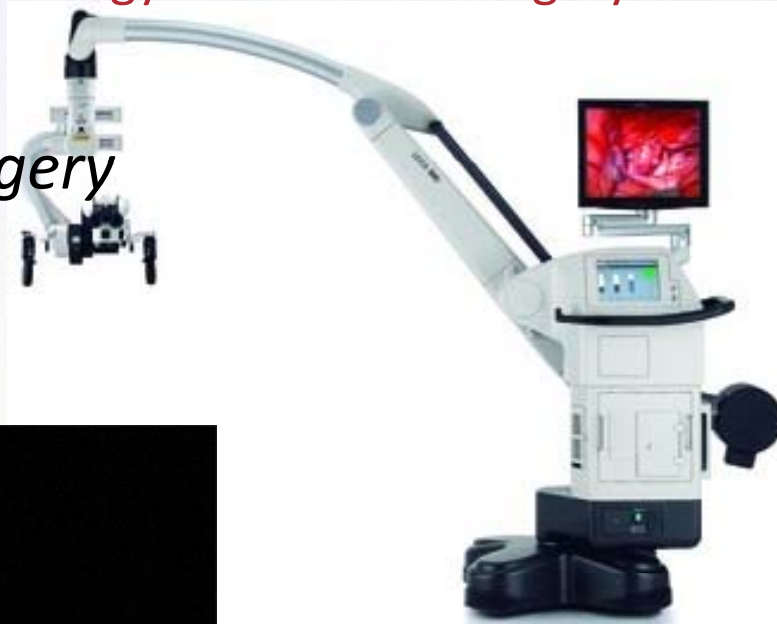

Advanced Technology- Microneurosurgery

- HIGH PRECISION

Minimally Invasive Surgery

- SAFETY PROTOCOLS



OPERATING MICROSCOPE



clearer view on magnification



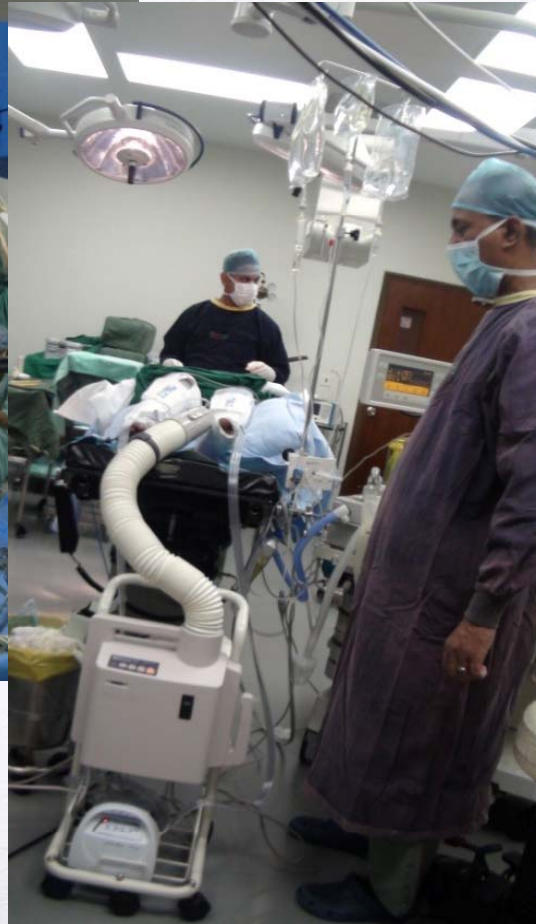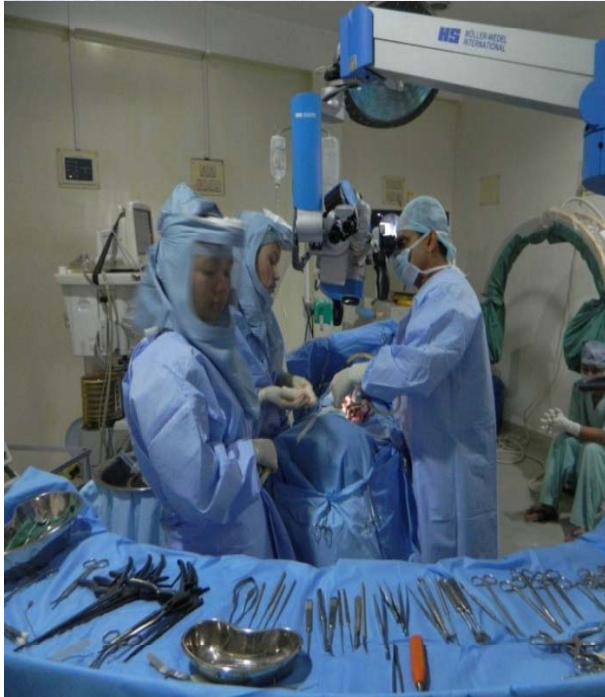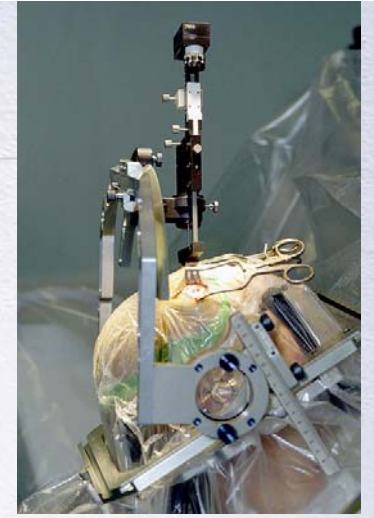
view without magnification



IMPROVED OUTCOME

NEUROSURGERY

TECHNOLOGY NEUROANAESTHESIA



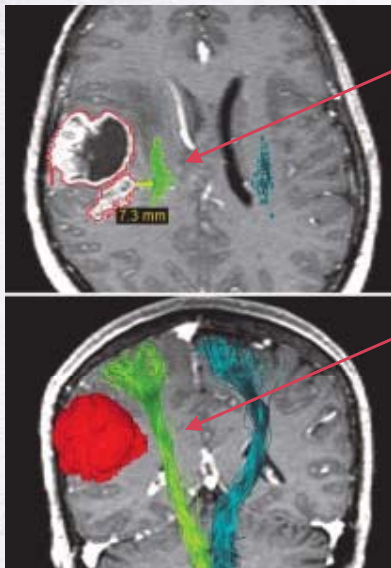
**SAFE & HIGH PRECISION
NEUROSURGERY**

**Special Equipments for
MINIMALLY INVASIVE
BRAIN & SPINE SURGERY**

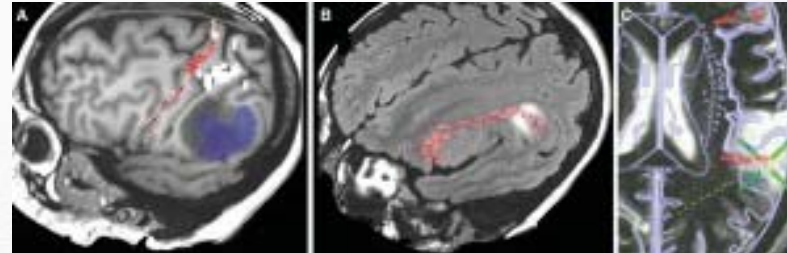
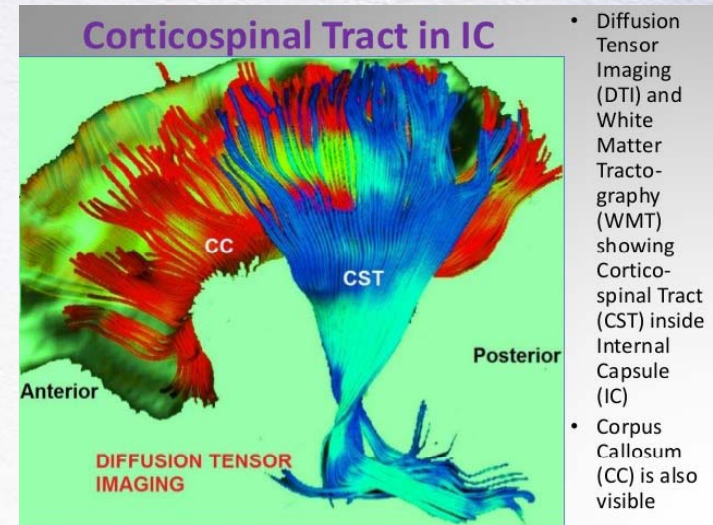
**NEUROSCIENCES
R N TAGORE HOSPITAL**



MRI-DIFFUSE TENSOR IMAGING(DTI)



Patient 1.
Motor Cortex- Glioma



Patient .2 left temporo parietal

AIM OF SURGERY:

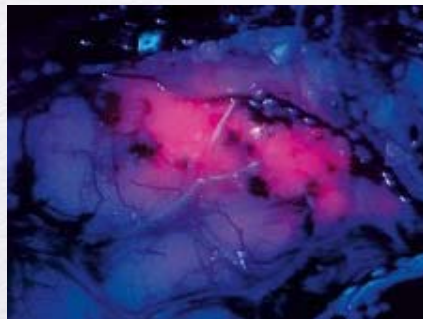
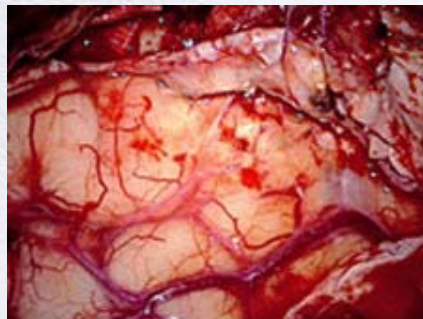
**MAXIMUM TUMOUR RESECTION AND
NO NEW NEUROLOGICAL MORBIDITY**

STRATEGIES: BRAIN TUMOUR SURGERY

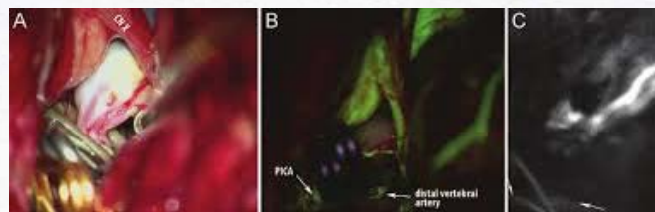


Advanced Technology- Microneurosurgery

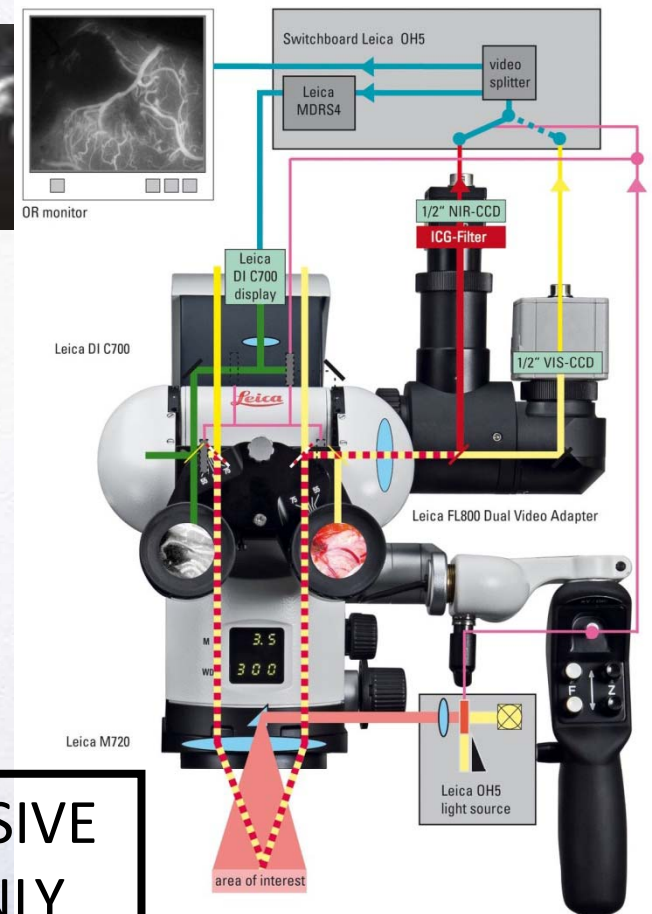
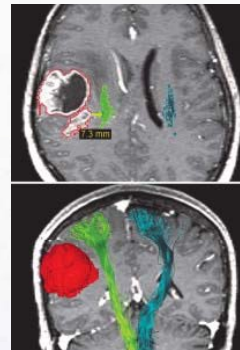
FLUORESCENCE GUIDED SURGERY



BLUE 400



ICG (Green)

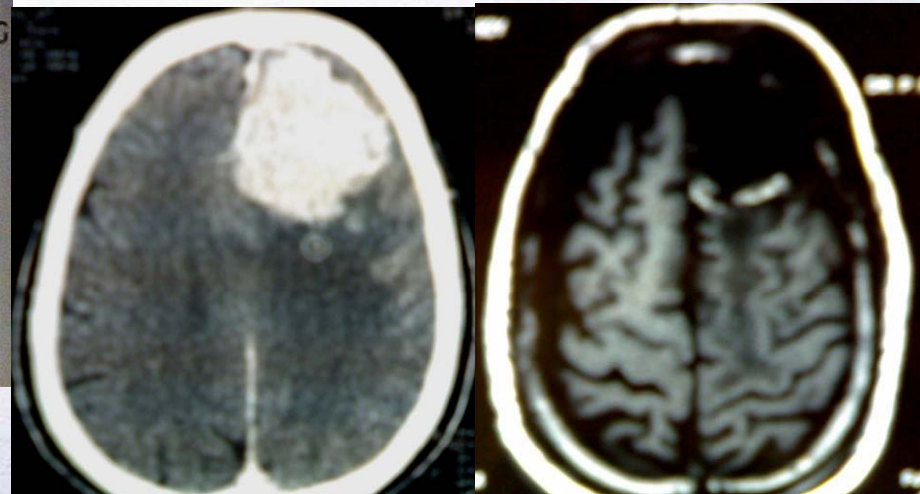
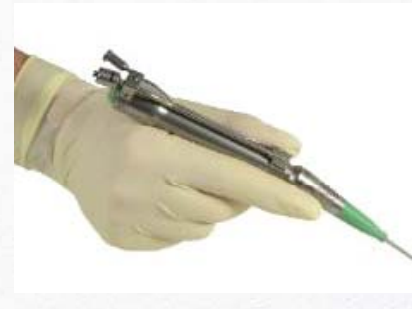


TUMOURS THAT ARE INVASIVE
HIGH GRADE GLIOMAS ONLY

BRAIN TUMOUR SURGERY



CUSA- CAVITRON ULTRASONIC SURGICAL ASPIRATOR

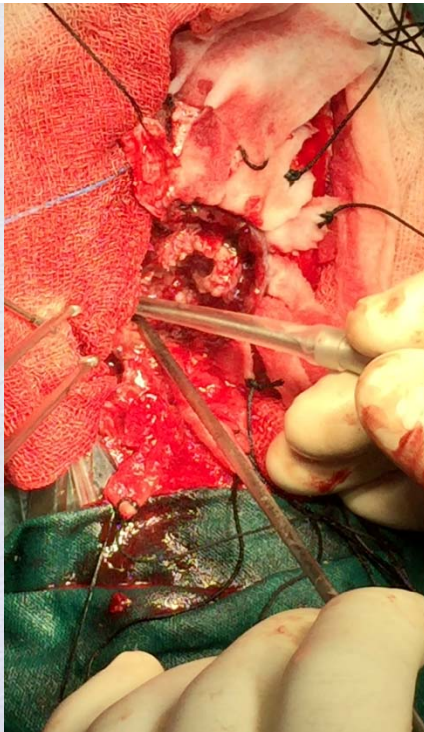
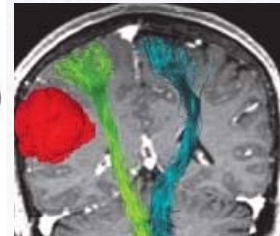
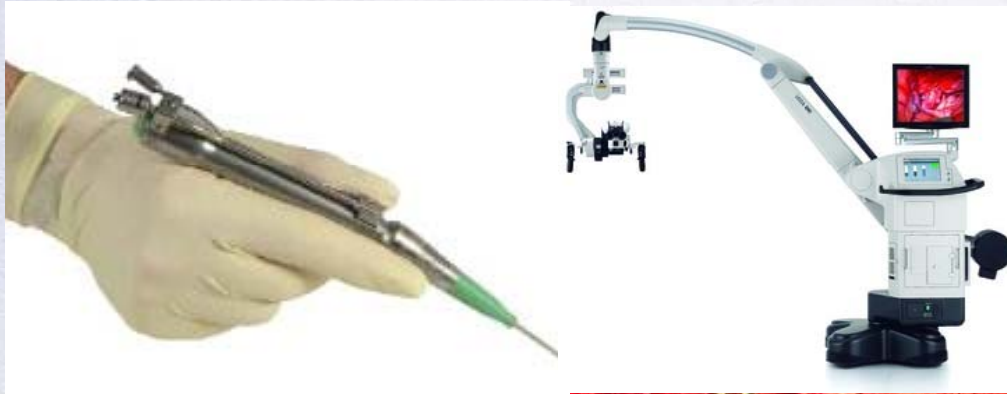

BRAIN TUMOUR SURGERY- Advanced Technology

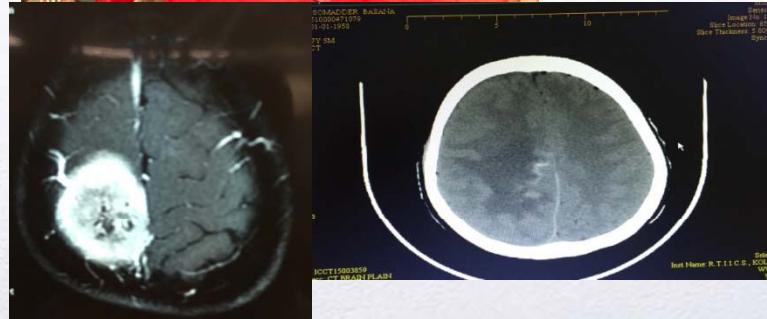
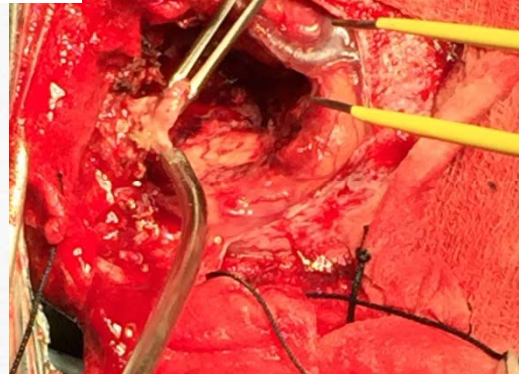


DIAGNOSIS: MENINGIOMA

Benign Tumor- normal life expectancy following surgery
Post operative - reversal of neurological deficit within a few days



VIDEO: CUSA



PRE OP MRI

POST OP CT

3RD POST OP DAY

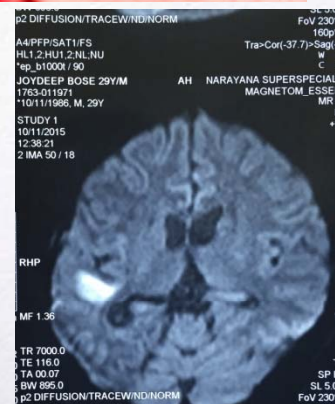
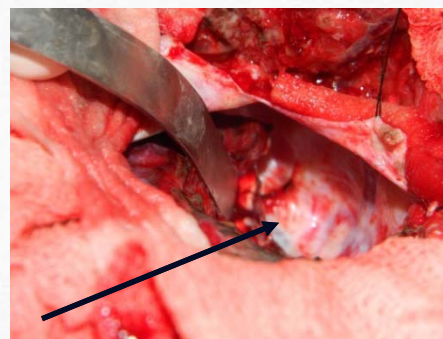
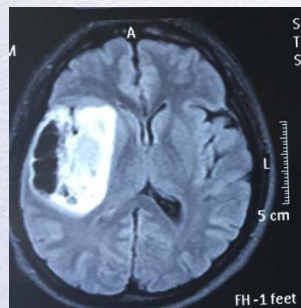
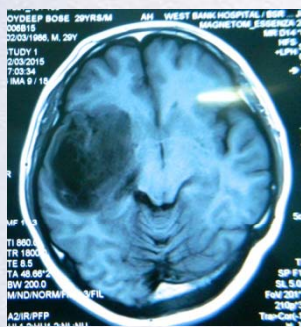
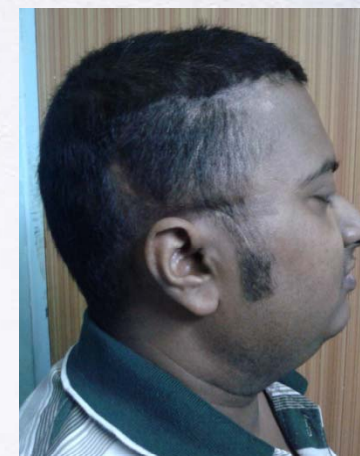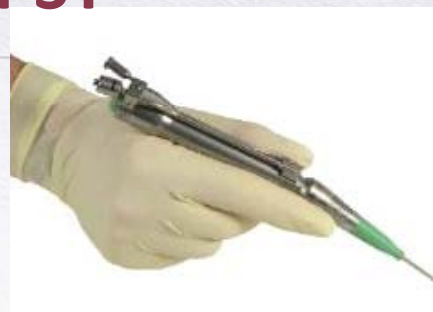LOW GRADE GLIOMA & EPILEPSY



22 YRS /M, JB
ABSENCE SEIZURES

ASTROCYTOMA GR II
Ki 67 - 0

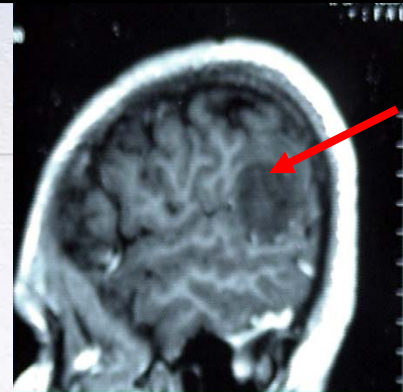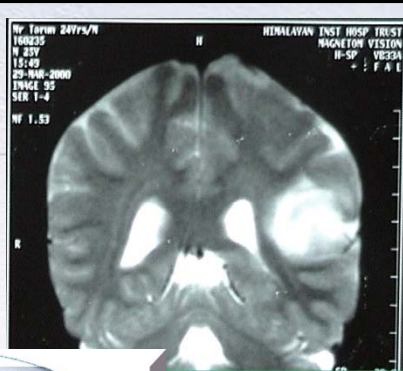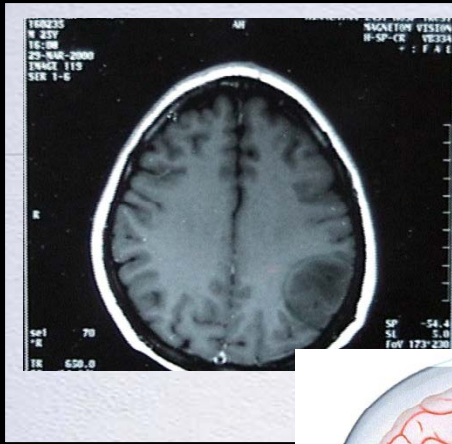GROSS TOTAL RESECTION
RADIOTHERAPY-IMRT



PRE OP MRI & MRS

POST OP MRI

1 YEAR POST OP
40

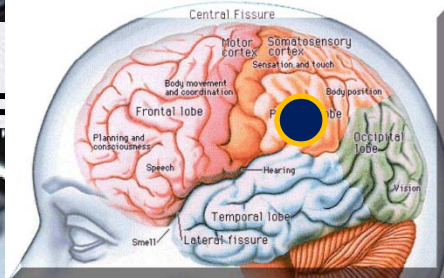


Seizures 15 Days

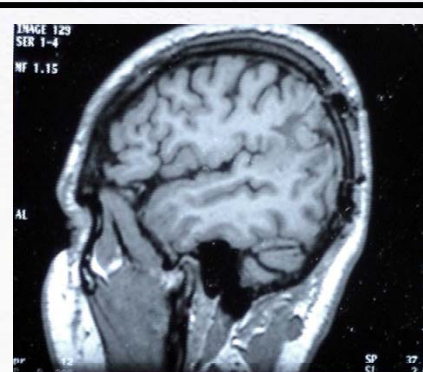
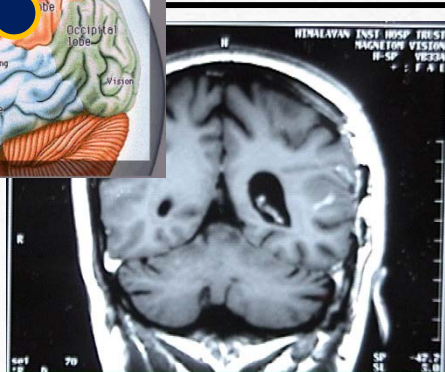
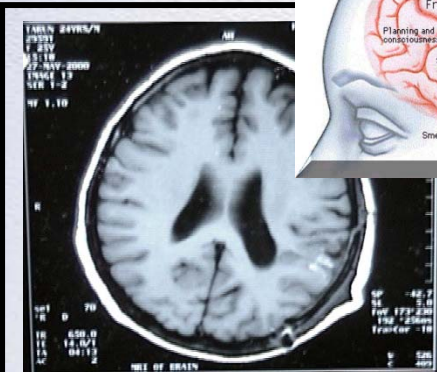
Astrocytoma Grade II

AWAKE SURGERY

Pre-Op MRI



Microsurgical
Radical Excision
Radiotherapy

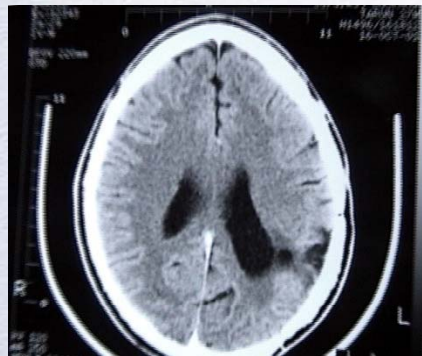

Follow up :

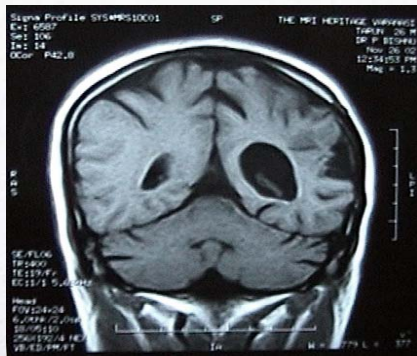Normal

Post-Op MRI

Functional
Status



CT Scan 1 Year



MRI at 2.5 Years



FU- 11 YEARS, NO RECURRENCE

Pituitary and Skull base tumours



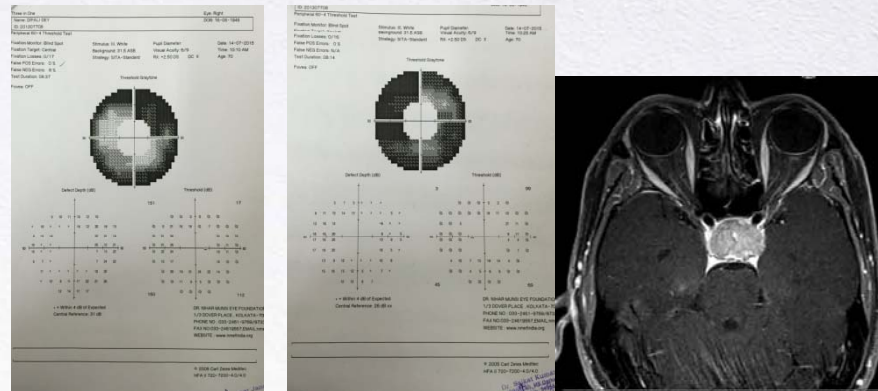
DD, 70 YRS , F,

PROGRESSIVE DIMINUTION OF VISION :

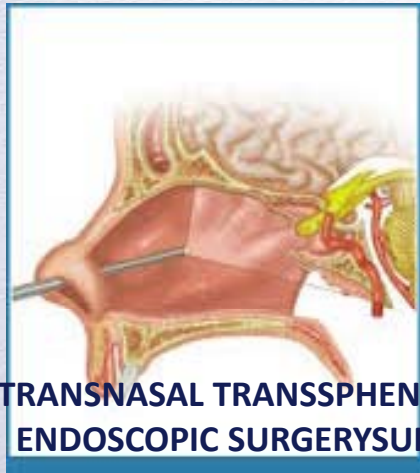
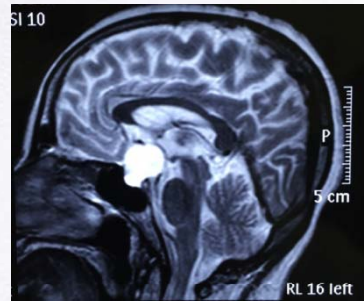
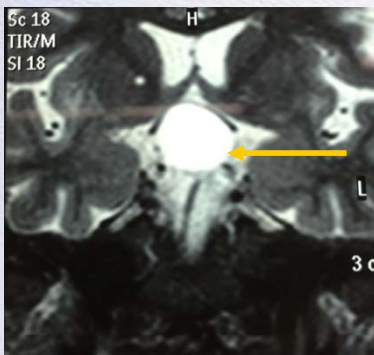
LEFT MORE THAN RIGHT

PITUITARY TUMOUR

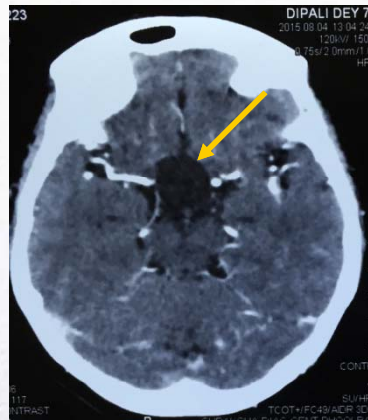HORMONAL STATUS NORMAL



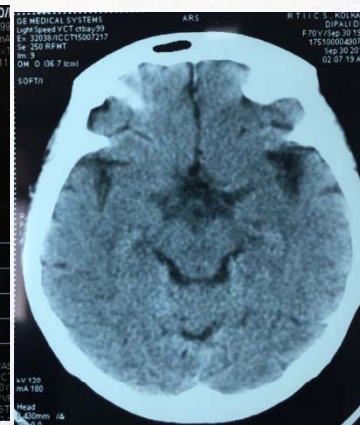
VISUAL FIELD PERIMETRY
CHIASMAL SYNDROME



TRANSNASAL TRANSPHENOIDAL
ENDOSCOPIC SURGERY

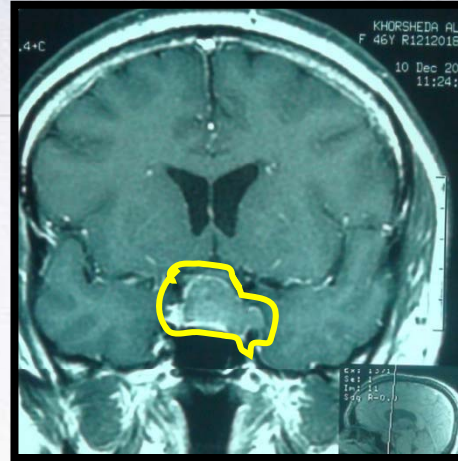
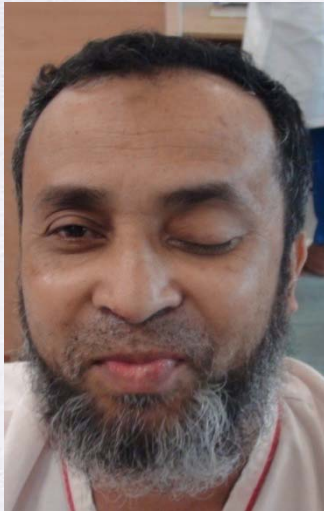

PRE OP CT SCAN

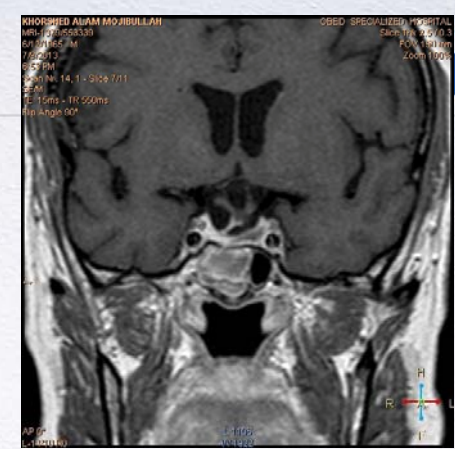


POST OP CT SCAN

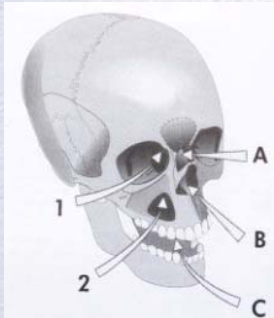
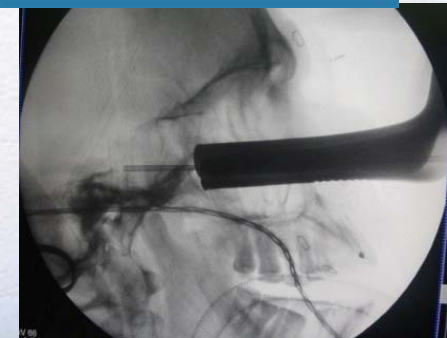
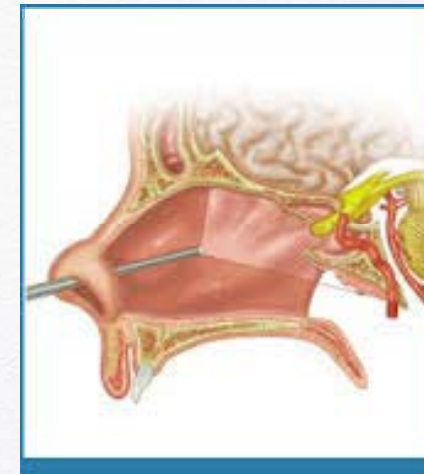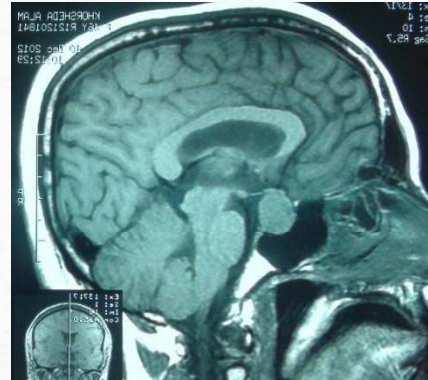54 YRS, SUDDEN PTOSIS PITUITARY ADENOMA



PRE OPERATIVE MRI SCAN



POST OPERATIVE MRI SCAN



ZISS optical excellence

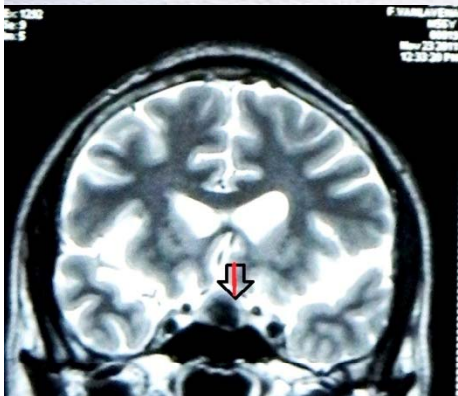
Experience ZISS optics from the base of the OMM into microscope. The better performance, through advanced micro-optics, image quality, improved resolution and contrast, and ZISS A technology that can range from 300 to 375 mm diameter with the maximum 1.8 class depth means that these microscope range are more ergonomically at your service. In combination with the ZISS optical excellence, you can see the world clearly and easily.

Micro-processor in the base of the microscope

Micro-endoscopic approach to skull base tumors

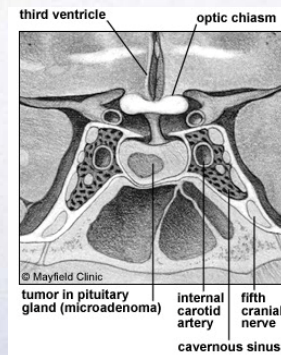
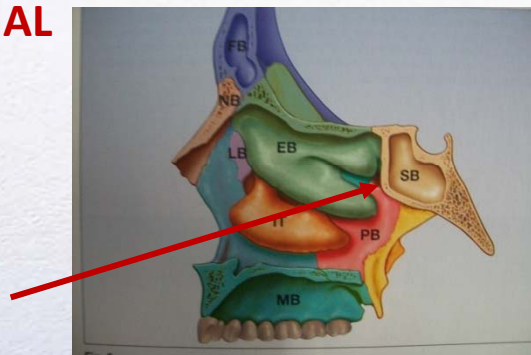
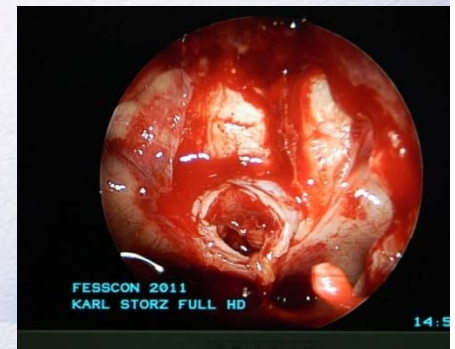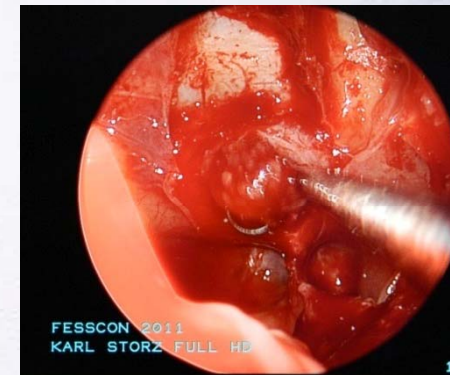

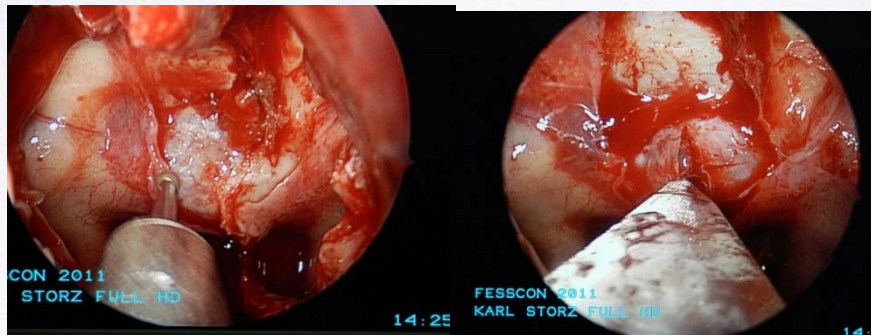

VIDEO: ENDOSCOPIC APPROACH



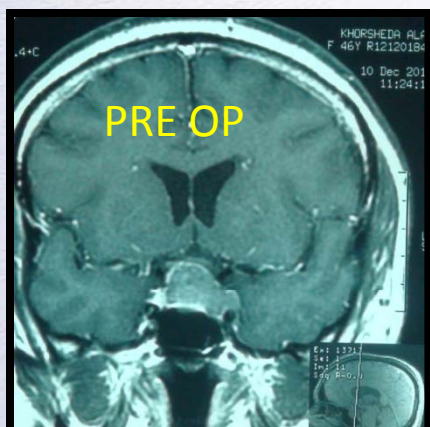
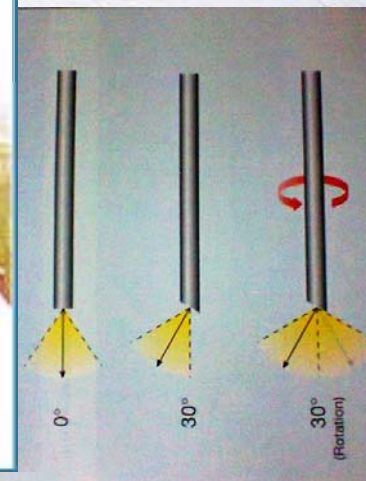
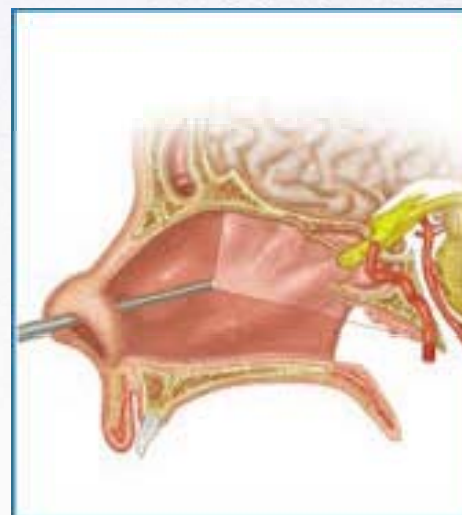
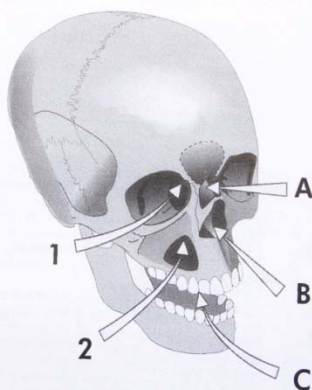
MICROADENOMA

**28 YM HEADACHE
VISUAL ACUITY NORMAL
INCREASED PRL**



MICRO-ENDOSCOPIC APPROACH TO SKULL BASE and PITUITARY TUMORS

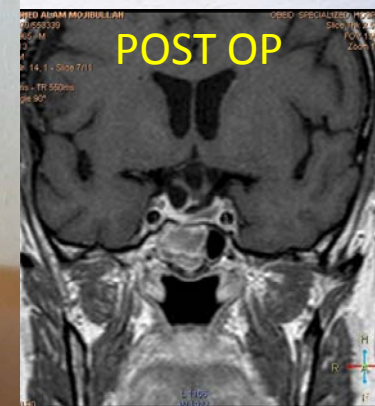MICROSCOPE



PRE OP



6 WEEKS POST OP



SEVERE HEADACHE

CHILDREN- DO NOT IGNORE RECURRING HEADACHE

MIGRAINE

BRAIN TUMOUR

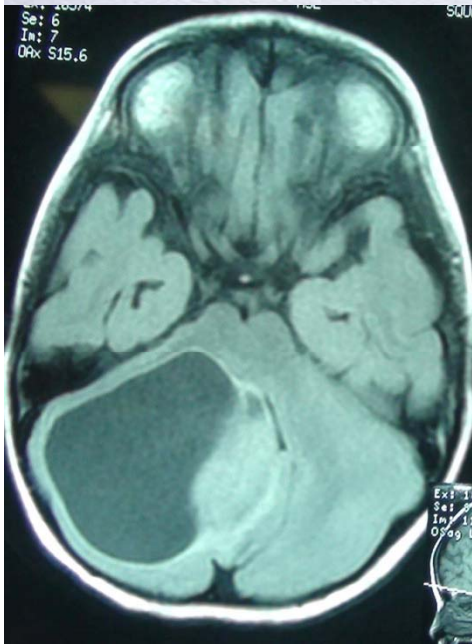
MENINGITIS



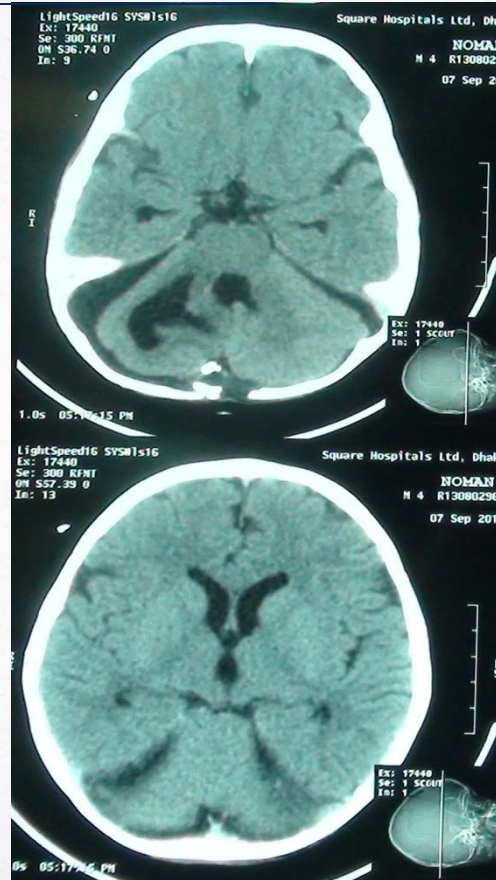
BRAIN TUMOUR SURGERY IN CHILDREN



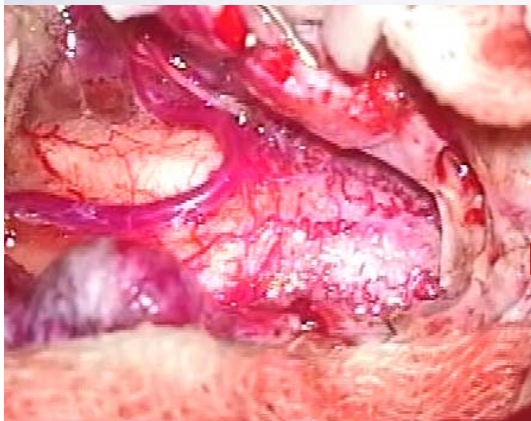
6 Years, Male,
FREQUENT FALLS
OCCASIONAL VOMITING
EARLY DX & PRECISION SURGERY



PRE OP MR SCAN



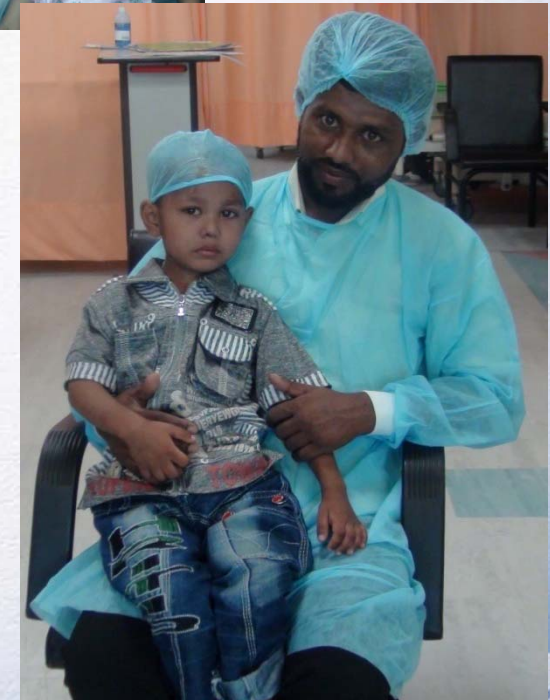
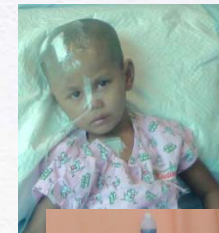POST OP CT SCAN



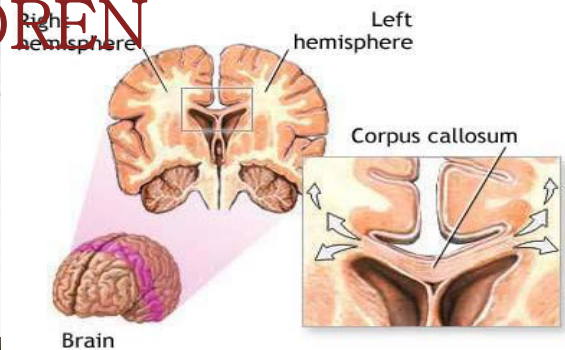
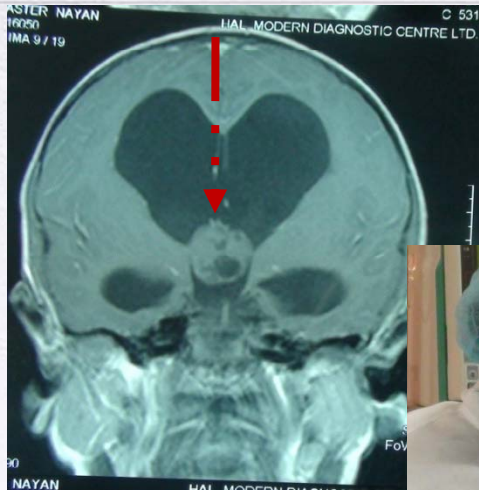
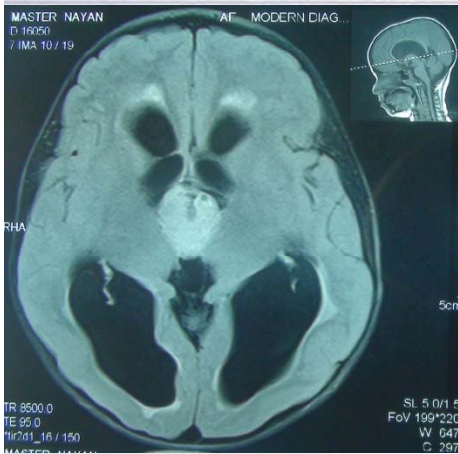MEDULLA

COMPLETE EXCISION
NO SHUNT REQUIRED

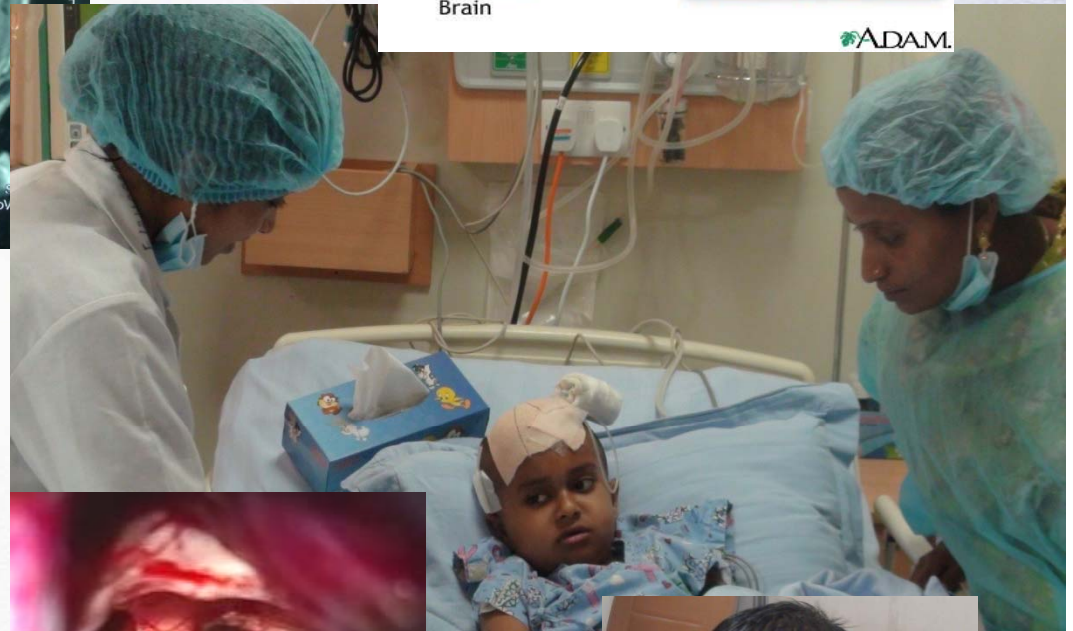
DX : PILOCYTIC ASTROCYTOMA
EXCELLENT OUTCOME



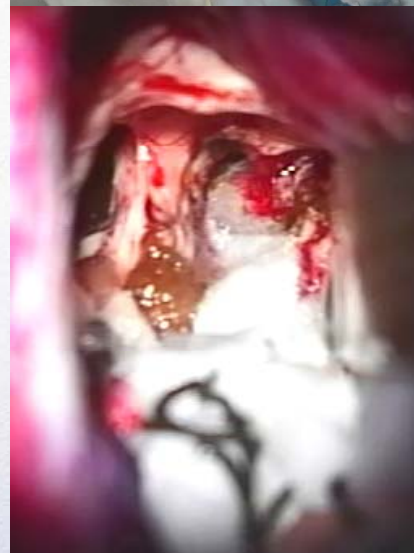
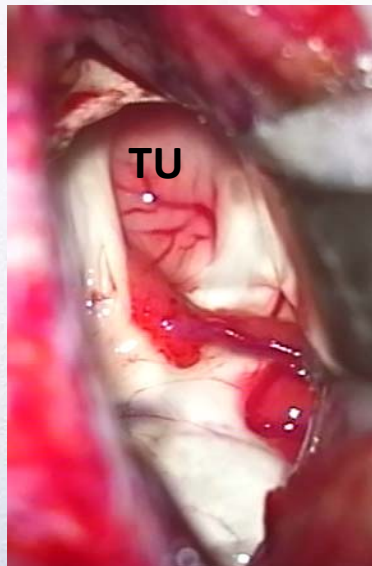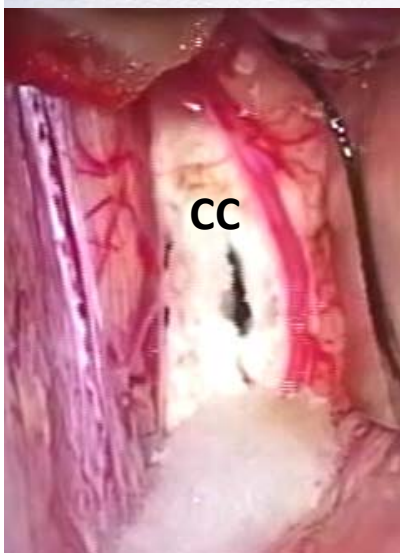
BRAIN TUMOUR SURGERY IN CHILDREN



ADAM



HIGH PRECISION SURGERY
SKILLED NURSING CARE





Become a Global
Leader in Medical
Devices Development,
High Quality Patient
Care, and Health
Sciences Studies by
2020....

**Sree Chitra Tirunal Institute of Medical Sciences &
Technology
Trivandrum, Kerala, India (South)**

**IMMUNOHISTOCHEMISTRY- Nature of the lesion
BIOLOGICAL MARKERS - Degree of Malignancy**

- 1. Ki 67**
- 2. IDH Mutation**



**Rajiv Gandhi Cancer Institute & Research Centre
New Delhi**

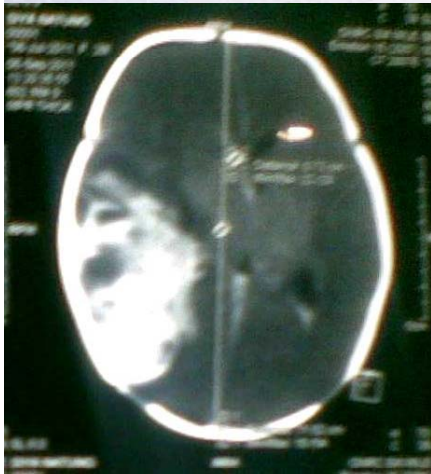Improving the Outcome.....

PEDIATRIC NEUROSURGERY

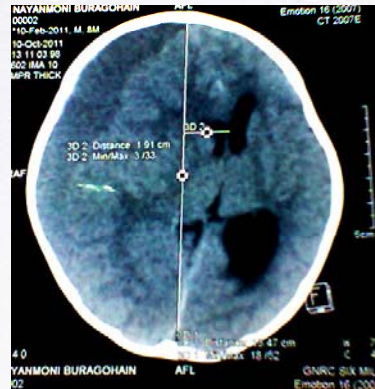
Brain & Spine Surgery



STROKE IN CHILDREN < 1YEAR

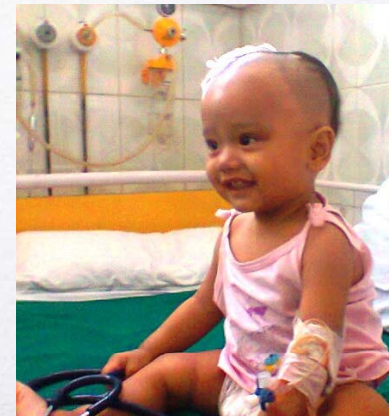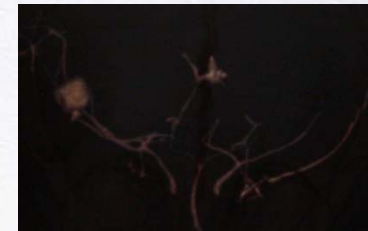
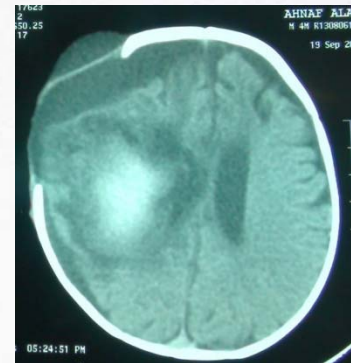


1. LARGE ICH



2. LARGE SUBDURAL HEMATOMA

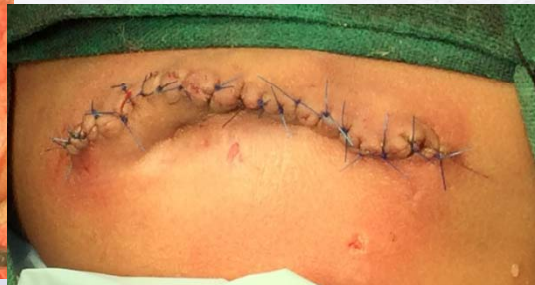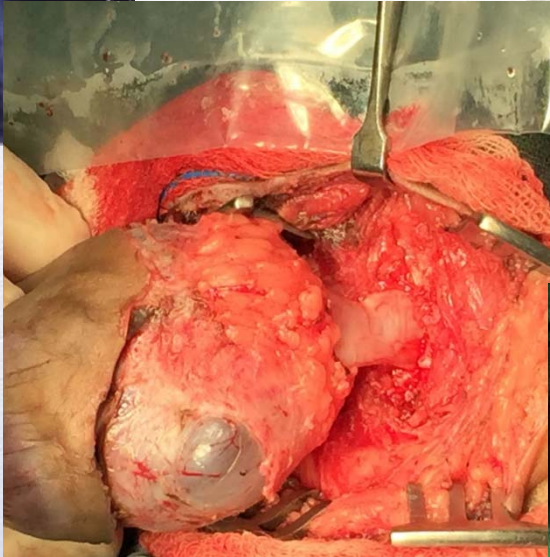
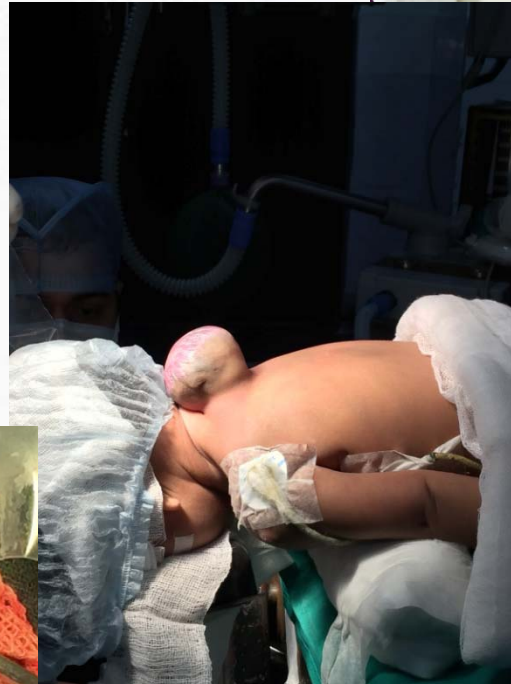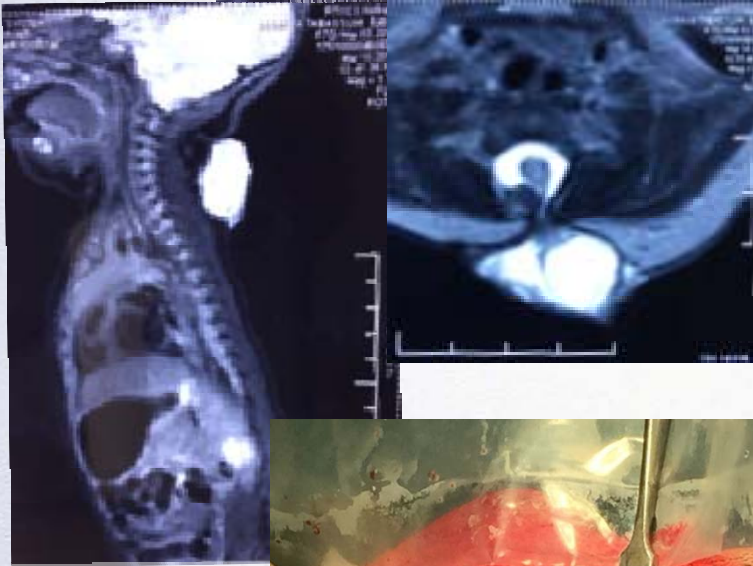
3. LARGE ICH with MCA ANEURYSM



PEDIATRIC SPINAL ANOMALIES:

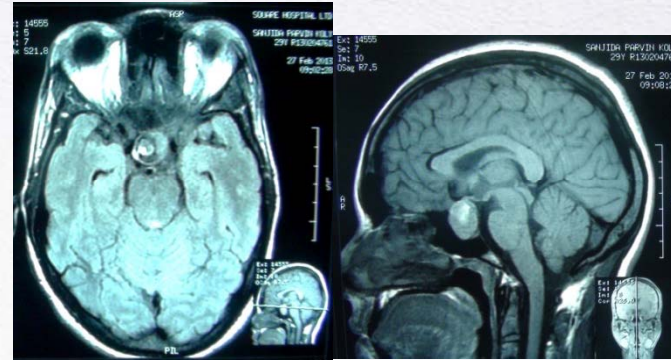

SPINAL DYSRAPHISM

MENINGOMYELOCOELE

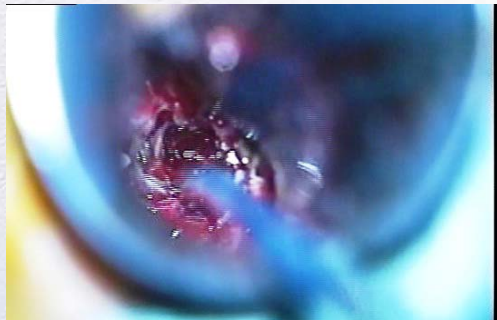


Pituitary adenoma- Growth Hormone- Acromegaly

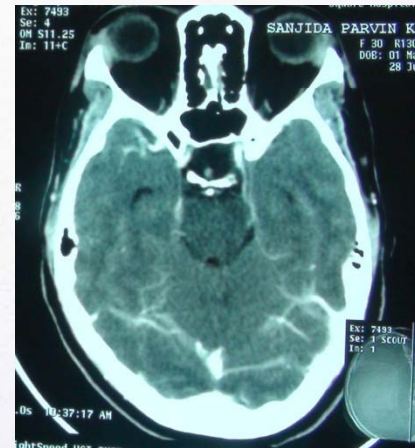
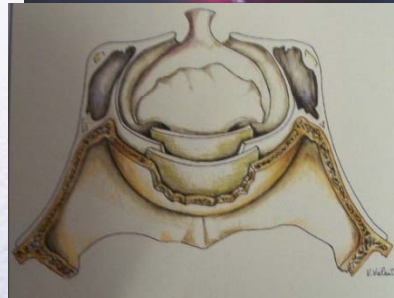
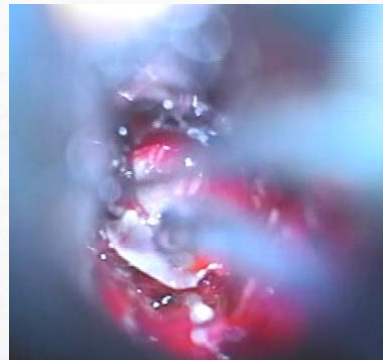
**SPK 25 Y F: HEADCAHE
FACIAL DYSMORPHISM**



PRE OP MRI SCAN



**TRANSSPENOIDAL
RESECTION**



POST OP CT SCAN



IMPROVED OUTCOME BRAIN & SPINE SURGERY



**STRATEGIES FOR SAFETY
AND PRECISION
FOR
BEST OUTCOME**



MT.KANCHENDJONGA

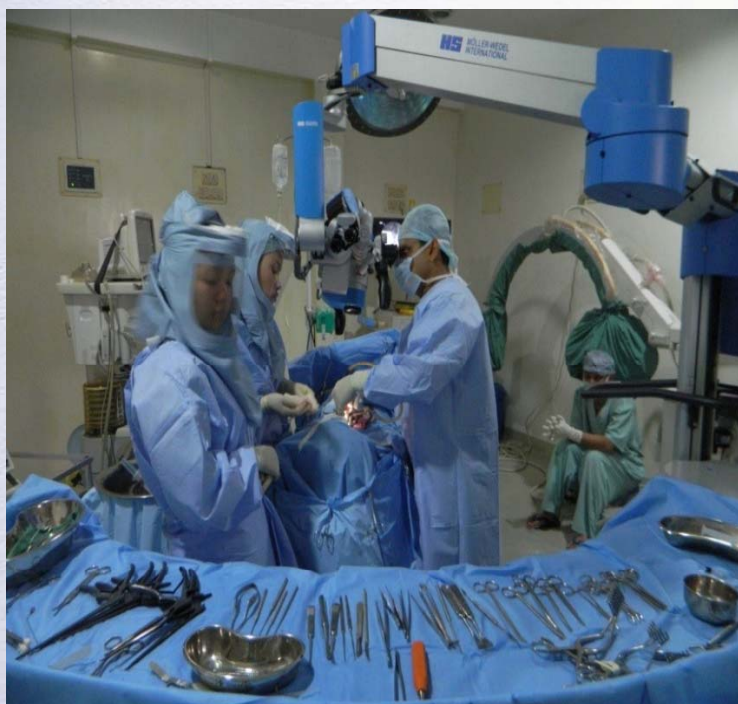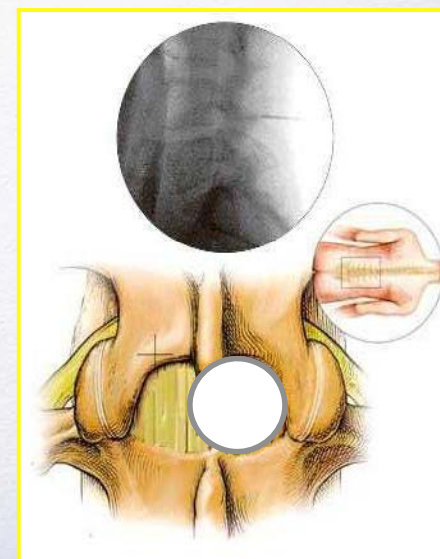
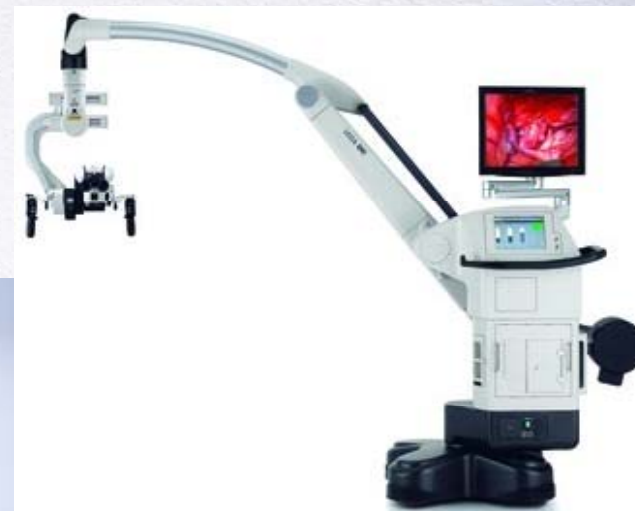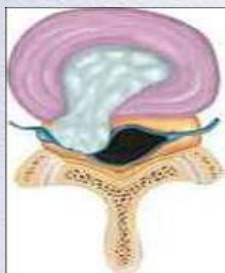
NEURO ONCOLOGY PROGRAM

BRAIN & SPINAL TUMORS

**RTIICS, R N TAGORE HOSPITAL, Mukundapur, Kolkata ,
&
Narayana Superspecialty Hospital, Andul, Howrah
(West bank-2)
INDIA**



TECHNOLOGY FOR HIGH PRECISION SPINAL SURGERY



INSTITUTE OF NEUROSCIENCES



SAFETY

বর্ধতি নিরাপত্তা

TEAM AVAILABLE: 24X7

NEUROSURGEONS

NEURO PHYSICIANS

NEUROANESTHESIST & CRITICAL CARE

NEURO ITU WITH HDU

RADIATION ONCOLOGIST

MEDICAL ONCOLOGIST

NEURONURSES FOR TRAUMA, STROKE AND POSTOP.



NURSES TRAINED IN NEUROCARE NEURO INTENSIVE AND POST OPERATIVE CARE



**NEUROSCIENCES
R N TAGORE HOSPITAL**